

I-1. PROJECT RESEARCHES

Project 5

PR5 The effect of BNCT on normal tissues

M. Suzuki

Institute for Integrated Radiation and Nuclear Science, Kyoto University

In 2020, accelerator-based boron neutron capture therapy (BNCT) for head and neck cancer was approved by Japanese Ministry of Health, Labor, and Welfare. At two medical institutes, BNCT for head and neck cancer has been started under the insurance coverage.

At Institute for Integrated Radiation and Nuclear Science, Kyoto University (KURNS), BNCT for body trunk tumors such as malignant pleural mesothelioma, liver tumors, and breast cancers had been carried out using Kyoto University Research Reactor (KUR) until 2019. These malignancies will be expected to be treated with accelerator-based BNCT in the medical institutes. For planning clinical trials of BNCT, the preclinical studies are very important. Especially the scientific findings on safety of BNCT are indispensable for first-in-men clinical trials. Therefore, I have started this project investigating the effect of BNCT on normal tissues or organs. Unfortunately, due to shortening of operation of KUR in 2022, three of six researches were not carried out. Details of three projects are referred to each progress report. I hope that this project will arouse much interest in BNCT researchers and shed new light on radiation biology.

P5-3: Phenotypic Change of Macrophage/Microglia in the Brain after BNCT.

Glioblastoma (GBM) had been treated with BNCT using Kyoto University Research Reactor (KUR) until 2019. With BNCT, better control and survival benefit was achieved. However, adverse effects such as brain edema or brain necrosis may sometimes occur after BNCT. It is known that microglia and macrophages change phenotype to control the inflammation in brain. Typically, M1 type is known to induce inflammation and M2 type is known to reduce inflammation in tissue repair.

In this study, the phenotypic change of microglia/macrophage after BNCT in the surrounding normal brain in glioma bearing mice. At 2 days after BNCT, M1 marker tended to increase compared to non-irradiated control. At 8 days after BNCT, M2 marker tended to increase compared to non-irradiated control.

P5-4: The effect of boron neutron capture therapy (BNCT) on esophagus in mice

Boron neutron capture irradiation (BNCR) using borono-phenylalanine (BPA) to whole thorax of mice induced severe weight loss and death within one week when irradiation time was over 20 minutes. We speculated the cause of the severe acute adverse events was ascribed to the damage of esophagus. According to the report investigating the effect on esophagus by X-ray irradiation, we examined the change of numbers of basal cells in esophageal membrane. The number of basal cells was lowest at 7 days after BNCR to the whole thorax. In further experiments, the number of the basal cells at 7 days after various treatment will be compared to investigate the effect of BNCT on esophagus.

P5-6: The Influence of Boron Neutron Capture Therapy on Bone Grow in Young Mice.

According to the experiment performed in this project last year, the tibial growth in the young mice was slightly suppressed in the higher dose of boron neutron capture irradiation (BNCR) using BPA. In this year, the pathological analysis was carried out to elucidate the morphological change of bones in young mice at 3 months after BNCR.

The tibias were collected from the mice of the following the four cohorts, Control (no irradiation), X-ray irradiation, Neutron irradiation, and BNCR. Histological changes in the tibias in the young mice after BNCR were less than dose in the X-ray group.

PR5-1 Phenotypic Change of Macrophage/Microglia in the Brain after BNCT

N. Kondo¹, Y. Sakurai¹, T. Takata¹ and M. Suzuki¹

¹ Institute for Integrated Radiation and Nuclear Science, Kyoto University (KURNS)

INTRODUCTION: Boron Neutron Capture Therapy (BNCT) have been applied to recurrent malignant glioma and even after standard therapy (surgery, chemo-radiation therapy) because of the selective damage to the tumor. Especially, glioblastoma (GBM) is the most miserable cancer, whose patient survival is 14.6 months and remarkably resistant to chemo-radiation and immunotherapy. With BNCT, we achieved better local control and survival benefit in malignant glioma using thermal neutrons produced by the reactor in Kyoto University. However, adverse effects (brain edema or brain necrosis, etc) may sometimes occur after BNCT. Microglia and macrophages change phenotype to control the inflammation in brain. Typically, M1 type is known to induce inflammation and M2 type is known to reduce inflammation in tissue repair. In this study, we examined the phenotypic change of microglia/ macrophage after BNCT in the surrounding normal brain in glioma bearing mice.

EXPERIMENTS: We implanted 2×10^5 GL261 murine glioma cells in the C57BL/6 mouse brain stereotactically after anesthesia. About two weeks later, we administrated 500mg/kg of boronophenylalanine (BPA) subcutaneously and irradiated thermal neutrons to mouse brain in the Heavy Water Neutron Irradiation Facility of the KUR.

We collected brains with time course (2, 8, and 14 days) after BNCT and fixed them in 10 % formalin, replaced with 10 to 20 % sucrose and kept samples in deep freezer.

We immune-stained the thin-sliced tissue with M1 (iNOS: inducible nitric oxide synthase) and M2 (CD206, Macrophage mannose receptor 1) markers.

RESULTS: We showed the tissue of non-irradiated control and 2days after BNCT stained with M1 marker in fig. 1A and B respectively. After 2 days, M1 marker tended to increase compared to non-irradiated control.

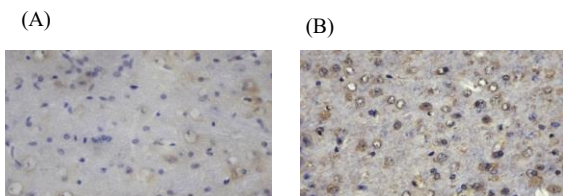


Fig.1. Typical immunostaining of brain tissue with M1 marker, iNOS in non-irradiated control (A) and 2 days after BNCT (B) .

Next, we showed the tissue of non-irradiated control and 8 days after BNCT stained with M2 marker in fig. 2A and B respectively. After 8 days, M2 marker tended to increase compared to non-irradiated control.

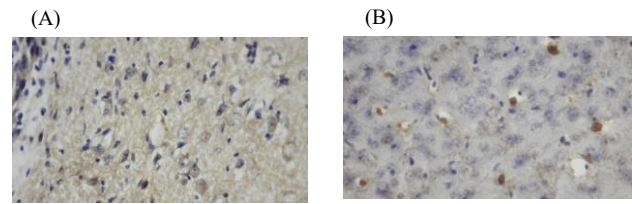


Fig. 2. Typical immunostaining of brain tissue with M2 marker, CD206 in non-irradiated control (A) and 8 days after BNCT (B) .

We will continue to immune-staining of these samples till we obtain enough numbers of samples.

PR5-2 The effect of boron neutron capture therapy (BNCT) on esophagus in mice

M. Suzuki, H. Tanaka, Y. Sakurai, T. Takata
*Institute for Integrated Radiation and Nuclear Science
Kyoto University*

INTRODUCTION: In 2020, accelerator-based boron neutron capture therapy for head and neck cancer was approved by Japanese Ministry of Health, Labor, and Welfare. At two medical institutes, BNCT for head and neck cancer has started under the insurance coverage.

For BNCT to be applied to other malignancies such as lung cancer or liver cancers, the effect of BNCT on normal tissues should be investigated. To investigate the effect of BNCT on lung tissues, we performed boron neutron capture irradiation (BNCR) to whole thorax of mice using boronophenylalanine (BPA) as a boron compound. In the cohort of mice irradiated for 30-m BNCR, all the mice were dead within 7 days after the irradiation. No apparent abnormality was observed in the extracted lungs from the dead mice.

We speculated that cause of death would be acute side effect of the esophagus since esophagitis is known to acute side effect in radiotherapy for lung cancer or esophageal cancer. Ando et al. reported the effect of X-ray irradiation on cell kinetics of esophageal membrane cells in mice. According to this report, numbers of basal cell decreased up to 4 days after the irradiation, then rapidly increased. With reference to this report, we investigated the effect of BNCT on esophagus using mice.

EXPERIMENTS:

Mice

Ten- to twelve-week-old female C3H/He mice were used. The mice were purchased from Japan SLC, Inc.

BNCR and measurement of thermal neutron and γ -ray

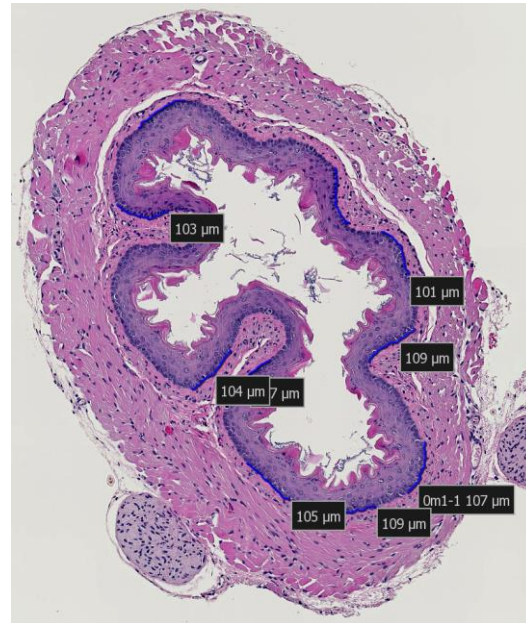
In this study, BPA was administered subcutaneously at the dose of 500 mg/kg before the whole thorax irradiation. At the each BNCR, three mice were held within a specially designed acrylic box. LiF plates (5-mm thick) were used to shield the whole body except for chest.

Neutron fluences were measured by radio activation of gold foils (3mm diameter; 0.05 mm thick) on the anterior and dorsal surface of the mice. Thermoluminescent dosimeters were used for γ -ray dosimetry.

Assessment of numbers of basal sells in mouse esophageal membrane

The extracted esophagus was fixed in the 10% neutral formaldehyde. The fixed samples were processed for preparation of the section and hematoxylin-eosin (HE) staining. Using a software, basal cell numbers per 90-120 μ m length were counted at 10 parts in each sample as shown in Fig.1.

Fig.1. HE staining of mouse esophagus.



RESULTS

Dosimetry

The anterior and posterior surface of mice were irradiated with thermal neutron beam at the thermal neutron flux of 5.3 and 1.3 n/cm²/s, respectively. The γ -ray was irradiated at the dose rate of 0.045 Gy/min.

Change in numbers of esophageal basal cells after BNCR

To investigate the change of numbers of esophageal basal cell, BNCR with fixed irradiation time (20 min) was performed. Irradiated mice were sacrificed at 2, 4, 7, and 10 days after the BNCR. Three mice were irradiated at each timepoint. Fig.2 shows the numbers of esophageal basal cells at each time interval after BNCR.

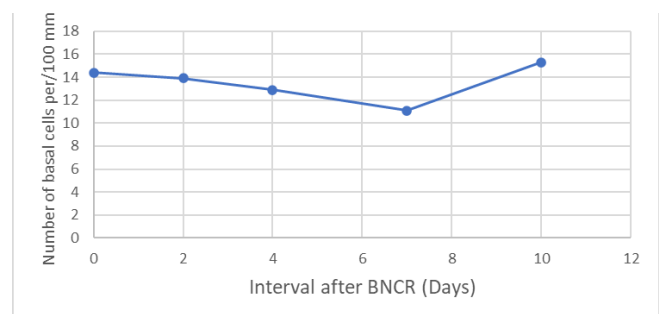


Fig.2. Change in number of esophageal basal cells after BNCR.

At 7 days after BNCT, the number of basal cells in esophageal membrane was lowest. In the further experiments to compare the effect of BNCR on esophagus at different fluence of thermal neutrons or X-ray irradiation, 7-day interval after BNCR will be selected for the assessment of the numbers of basal cells.

PR5-3 The Influence of Boron Neutron Capture Therapy on Bone Growth in Young Mice

R. Iwasaki, R. Yoshikawa, R. Kido, T. Mori, K. Ono¹, Y. Sakurai², and M. Suzuki²

Faculty of Applied Biological Sciences, Gifu University
¹Kansai BNCT Medical Center, Osaka Medical College
²Institute for Integrated Radiation and Nuclear Science, Kyoto University

INTRODUCTION:

There are various tumors in which normal bone is included in the irradiation field, such as bone and soft tissue sarcoma, head and neck cancer, gynecologic cancer, prostate cancer, and tumors that have metastasized to the bone. In particular, there is a high incidence of bone tumors such as osteosarcoma, chondrosarcoma and Ewing's sarcoma in the adolescent and young adult generation. As a result, radiation-induced bone toxicity, such as fracture, necrosis, and impairment of skeletal growth, can be occurred.

On the other hand, compared with the X-ray irradiation, boron neutron capture therapy (BNCT), a tumor cell-selective particle radiation therapy, is considered to be more effective without any late effects to the normal bone. However, in our previous study using the adult mice, the higher accumulation was seen in the epiphyseal cartilage including the growth plate. This finding indicates that the higher radiation doses might be delivered to the growth plate and may cause the impairment of skeletal growth.

Last year in this project, we found that the tibial growth in the young mice was slightly suppressed in the higher doses of BNCT. Therefore, in this year, we investigated the pathological analysis to elucidate the morphological change of bones in young mice 3 months after irradiation.

EXPERIMENTS: Female four-week-old C3H/He mice were used for the study (n = 5 in each group). As boron compound, p-boronophenylalanine (BPA) was prepared at a dose of 30 mg/ml. The X-ray and neutron irradiation was performed at Gifu University and Kyoto University Reactor, respectively.

X-ray irradiation Mice were irradiated at a dose rate of 250 cGy/min to their right hind limb at single doses of 4, 8, 12, 16, 20, 24, 28, 32 and 36 Gy. Non-irradiated mice were also set as a control.

Neutron irradiation Each neutron irradiation at a power of 1 MW was carried out as follows; neutron beam only (for 30 or 60 min), neutron beam for 30 or 60 min after subcutaneously injected into mice at doses of 125, 250, and 500 mg/kg of BPA. Based on the results of the biodistribution of BPA, irradiation was started at 30 min after the injection.

Histological analysis Tibias were collected at 12 weeks post-irradiation. Subsequently, the specimens were decalcified in 10% formic acid, dehydrated with graded ethanol and embedded in paraffin. The 5- μ m longitudinal histological sections of the epiphysis were stained with Hematoxylin and Eosin.

RESULTS:

In the specimens of the growth plate region from the control group, chondrocytes and hypertrophic chondrocytes

surrounded by the cartilage matrix were found in the lower growth cartilage (Fig. 1A & a). The pathological findings of 4 and 8 Gy irradiation in the X-ray group, those of neutron irradiation for 30 or 60 min in the neutron group, and those of neutron irradiation for 30 min after BPA 125, 250 and 500 mg/kg in the BNCT group were similar to those in the non-irradiated group (Fig. 1b-d).

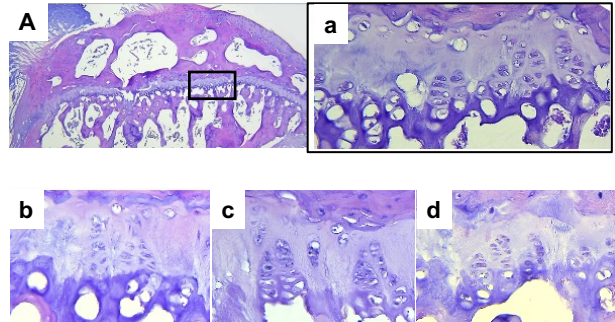


Fig. 1. Histological images of control (A, a), 8 Gy irradiation of X-ray (b), 30 min irradiation of neutron after 500 mg/kg of BPA (c) and 60 min irradiation of neutron (d).

In the growth plate from 12, 16 and 20 Gy irradiation of X-ray and 60 min irradiation of neutron after 125, 250 and 500 mg/kg of BPA, the regular arrangement of chondrocytes was disturbed, and increasing chondrocytes were found within the cartilage matrix (Fig. 2e & f). Besides the disturbance of the chondrocyte arrangement, the cartilage matrix was increased at 24 Gy irradiation of X-ray (Fig. G & g). A marked increase in cartilage matrix was observed at more than 30 Gy of X-ray (Fig. H & h). No increase in cartilage matrix was observed in the BNCT and neutron radiation groups.

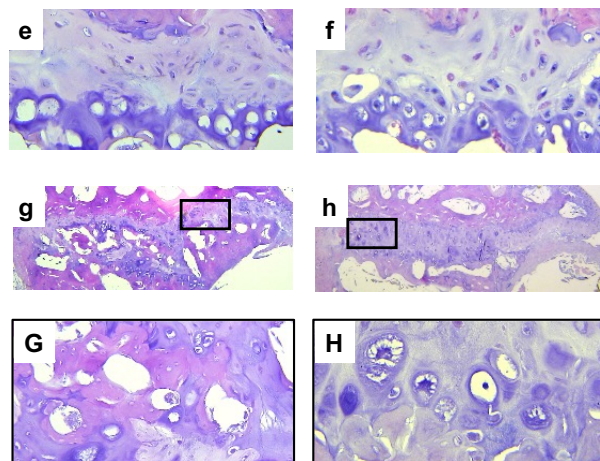


Fig. 2. Histological images of 20 Gy (e), 24 Gy (G, g), and 30 Gy (H, h) irradiation of X-ray and 60 min irradiation of neutron after 500 mg/kg of BPA (f).

CONCLUSION: The results show that the histological changes in the young mice after BNCT were less than those in the X-ray group. Further investigation to verify the effects of longer-term observation are warranted.