

A case of a systemic cancer-associated thrombosis successfully treated with multi-disciplinary treatment including anticoagulation therapy and anticancer drug therapy

Fumiya Yoneda , Yugo Yamashita *, Shin Watanabe , and Koh Ono

Department of Cardiovascular Medicine, Kyoto University Hospital, 54, Shogoin Kawahara-cho, Sakyo-ku, 606-8507, Kyoto, Japan

Received 19 December 2022; revised 30 September 2023; accepted 16 October 2023; online publish-ahead-of-print 18 October 2023

Background

Cancer-associated thrombosis (CAT) is one of the major complications during the treatment course of cancer, which often challenges clinicians in daily clinical practice despite anticoagulation therapy.

Case summary

A 57-year-old man with a history of a liver transplantation was diagnosed with post-transplant lymphoproliferative disorders. He developed severe systemic thromboses including a massive pulmonary embolism and was treated with anticoagulation therapy including a factor Xa inhibitor. However, the systemic thromboses worsened despite the anticoagulation therapy. During the acute treatment course of the thromboses, we administered anticancer drug therapy in hopes of an improvement in the activity of the cancer status leading to a favourable effect on the thrombosis status. Multi-disciplinary treatment including anticoagulation therapy and anticancer drug therapy successfully improved the systemic thrombosis.

Discussion

Anticoagulation therapy is a standard treatment for CAT; however, some cases of CAT do not successfully improve despite anticoagulation therapy, partly due to a highly active cancer status. Anticancer drug therapy might increase the risk of a thrombosis, whereas it could improve the activity of the cancer status leading to a decreased risk of a thrombosis. A multi-disciplinary therapy might be a reasonable option especially for CAT with a highly active cancer status.

Keywords

Cancer • Thrombosis • Pulmonary embolism • Anticoagulant

ESC Curriculum

9.5 Pulmonary thrombo-embolism • 9.4 Thrombo-embolic venous disease

Learning points

- Some cases of cancer-associated thrombosis may have difficulty in improving the thrombosis despite anticoagulation therapy.
- Anticancer drug therapy can improve the activity of the cancer status leading to a decreased risk of thromboses.
- Multi-disciplinary therapy including anticoagulation therapy and anticancer drug therapy may be a reasonable option especially for severe thromboses with post-transplant lymphoproliferative disorder patients.

* Corresponding author. Tel: +81 75 751 4255, Fax: +81 75 751 3299, Email: yyamashi@kuhp.kyoto-u.ac.jp

Handling Editor: Giulia Ferrannini

Peer-reviewers: Michele Russo; Matteo Nicoletto

Compliance Editor: Zhiyu Liu

© The Author(s) 2023. Published by Oxford University Press on behalf of the European Society of Cardiology.

This is an Open Access article distributed under the terms of the Creative Commons Attribution-NonCommercial License (<https://creativecommons.org/licenses/by-nc/4.0/>), which permits non-commercial re-use, distribution, and reproduction in any medium, provided the original work is properly cited. For commercial re-use, please contact journals.permissions@oup.com

Introduction

Thromboses are one of the major complications in patients with cancer. A previous study reported patients with cancer develop venous thrombo-embolisms (VTEs) in 4–20% and arterial thrombo-embolisms in 4.7% during the treatment course of cancer.¹ Furthermore, cancer-associated thrombosis (CAT) has been reported to be the second leading cause of death in patients with cancer, and optimal management of CAT could have a significant impact on their prognosis.² Here, we experienced an interesting case of systemic thromboses including a massive pulmonary embolism (PE) with post-transplant lymphoproliferative disorders (PTLDs), where a multi-disciplinary therapy including anticoagulation therapy and anticancer drug therapy was effective in improving the severe thromboses associated with a highly active cancer status.

Summary figure

Two years ago	A liver transplantation was performed. Tacrolimus and everolimus were administered.
Just before admission	Fluorodeoxyglucose-positron emission tomography (FDG-PET) showed hyperaccumulation in the para-aortic, bilateral cervical, right axillary, and right inguinal lymph nodes.
Day 1	The patient was admitted to the hospital due to abdominal pain. Contrast enhanced computed tomography (CT) showed systemic thrombosis. Unfractionated heparin was administered.
Day 6	An endoscopic ultrasound-guided fine needle aspiration through the stomach was performed.
Day 9	The patient was intubated due to a sudden deterioration in his respiratory status. Contrast enhanced CT showed an exacerbation of the pulmonary artery thrombus and we began adjusting anticoagulation therapy.
Day 23	Chemotherapy (R-CHOP) was started.
Three months after discharge	Contrast-enhanced CT showed that the pulmonary embolism and deep vein thrombosis in the lower extremities had disappeared.
Six months after discharge	FDG-PET showed that the hyperintensities in lymph nodes had almost disappeared.

Case report

A male, whose height was 175.7 cm, body weight 99.5 kg, and body mass index 32.2 kg/m², underwent a liver transplantation at the age of 55 for cirrhosis due to non-alcoholic steatohepatitis and received tacrolimus and everolimus. After that, thrombocytopenia was observed, and his platelet count temporarily decreased to 5 × 10⁹/L (normal range: 109–384 × 10⁹/L). Because of the possibility of drug side effects and idiopathic thrombocytopenia, everolimus was discontinued, and eltrombopag and prednisolone were administered. At the age of 57, a computed tomography (CT) scan revealed lymphadenopathy, and fluorodeoxyglucose-positron emission tomography showed hyperaccumulation in the para-aortic, bilateral cervical, right axillary, and right inguinal lymph nodes, raising the suspicion of PTLD (Figure 1A). Tacrolimus was reduced from 3 to 2 mg. Soon after that, he was urgently hospitalized due to abdominal pain, and a contrast-enhanced CT scan showed thrombi in the portal vein, splenic artery, and

descending aorta and multiple hepatic infarctions, splenic infarction, PE, and deep vein thrombosis in the lower extremities (Figure 1B). At this moment, his platelet count was 55 × 10⁹/L, and haemoglobin was 11.3 g/dL (normal range: 11.5–16.7 mg/dL).
At that time, his vital signs were stable and cardiac and lung sound were normal and there was no leg oedema. Unfractionated heparin (UFH) was administered for systemic thrombosis. However, the activated partial prothrombin time (APTT) did not prolong to a therapeutic range even with 50 000 units/day of UFH, which was very high dose in Japanese daily clinical practice. There was no progression of thrombocytopenia after administering the UFH, and heparin-induced thrombocytopenia was not suspected because anti-platelet factor 4-heparin antibody was negative. The multi-disciplinary departments discussed the management strategy for the patient. Although the status of thrombosis was severe, his vital signs were stable at the time, and we thought that a direct biopsy from the enlarged abdominal lymph nodes that could cause abdominal pain was needed to rule out other diseases than diffuse large B-cell lymphoma

(DLBCL) and determine the treatment strategy urgently. On Day 6 after admission, the UFH was temporarily withdrawn, and an endoscopic ultrasound-guided fine needle aspiration (EUS-FNA) for abdominal lymph nodes through the stomach was performed. On Day 9, dyspnoea suddenly occurred, and his respiratory condition rapidly deteriorated. He was intubated due to shock vitals and was admitted to the intensive care unit. His heart rate was 96 b.p.m., systolic blood pressure 70–80 mmHg, and SpO₂ 99% under an FiO₂ of 60%. Blood tests showed his D-dimer level was over 40 µg/mL (normal range: <1.0 µg/mL), low antithrombin level of 73% (83.0–118.0%), platelet count was 94 × 10⁹/L, haemoglobin was 9.6 g/dL, creatinine levels was 1.46 mg/dL (0.65–1.07 mg/dL), and lupus anticoagulant test was negative. A contrast-enhanced CT scan revealed an exacerbated pulmonary artery thrombus (Figure 2A), and echocardiography showed a D shape of the left ventricle due to right ventricular enlargement. We diagnosed the patient with systemic thrombosis, including a severe PE presenting with shock vitals. Thrombolytic therapy was delayed because the patient was at a high

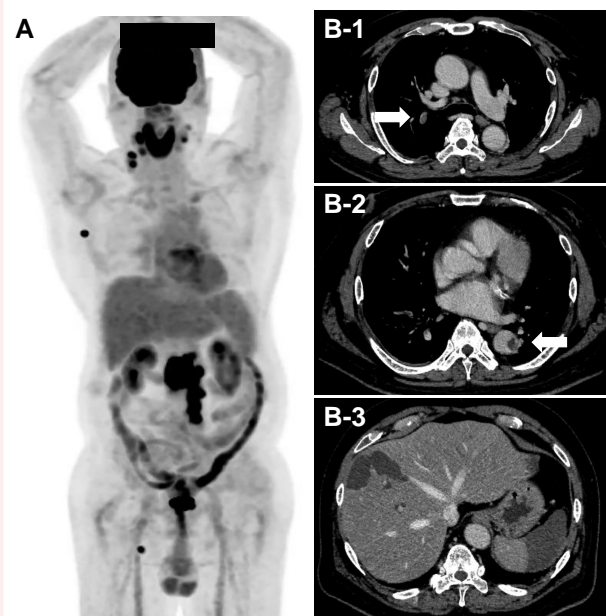


Figure 1 (A) The fluorodeoxyglucose-positron emission tomography computed tomography before the development of the systemic thrombosis revealed hyperaccumulation in the para-aortic, bilateral cervical, right axillary, and right inguinal lymph nodes. (B) Several days after the positron emission tomography-computed tomography, contrast-enhanced computed tomography showed multiple thrombi in the portal vein, liver artery, splenic artery, descending aorta (arrow), pulmonary artery (arrow), and bilateral popliteal veins.

risk of bleeding due to a history of EUS-FNA on Day 6 of admission and the risk of hepatic and splenic haemorrhagic infarctions. Percutaneous cardiopulmonary support was also delayed because of the risk of further thrombo-embolisms due to a descending aortic thrombus and bilateral femoral vein thrombus. Therefore, we decided to perform anticoagulation therapy with UFH while using vasopressors. Since the APTT did not adequately prolong even with 50 000 units/day of UFH, we switched the UFH to 7.5 mg/day of fondaparinux and continued for 7 days, considering the possibility of antithrombin-independent heparin resistance. After that, we started apixaban 10 mg b.i.d. and reduced to 5 mg b.i.d. 1 week later.

Since there was no prolongation of prothrombin time–international normalized ratio and no decrease in fibrinogen and anticardiolipin antibody-IgG, anticardiolipin glycoprotein-1 and lupus anticoagulant were not present in plasma, he was not diagnosed with disseminated intravascular coagulation or antiphospholipid syndrome. He was diagnosed with PTLD by EUS-FNA. Post-transplant lymphoproliferative disorder was considered to be the primary cause of the systemic thrombosis. In addition, drug-induced thrombophilia due to prednisolone and eltrombopag and thrombotic microangiopathy (TMA) due to tacrolimus were thought to be the secondary causes of the thrombosis. Then, the cause of the worsening thrombosis, including a severe PE, was considered to be inadequate anticoagulation due to heparin resistance. Even with apixaban treatment, contrast-enhanced CT on Day 21 showed that the systemic thrombus, including the thrombus in the pulmonary artery, was decreasing but still highly remained (Figure 2B). Since we considered treating the PTLD, which was thought to be the main cause of the systemic thrombosis, would be effective in improving the thrombosis in addition to the treatment for the cancer, chemotherapy was performed with rituximab 700 mg on Days 23 and 31, and 50% of the usual dose of

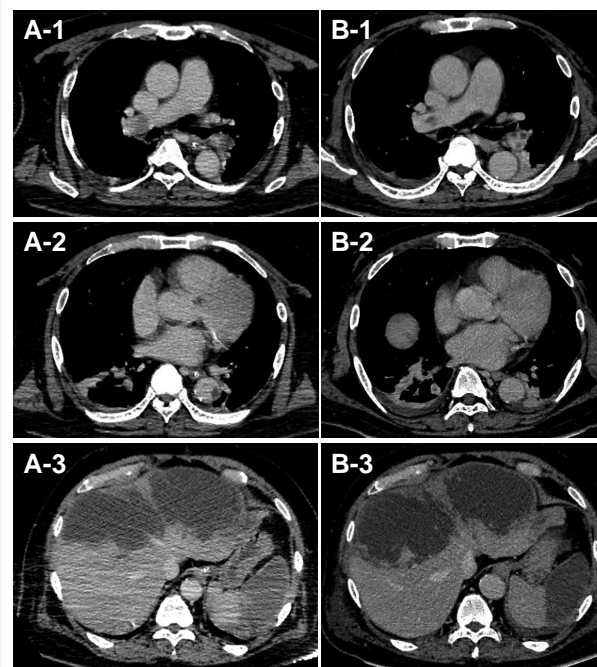


Figure 2 (A) Contrast-enhanced computed tomography on Day 9 showed an exacerbation of the systemic thrombotic embolisms. (B) Fourteen days after prescribing anticoagulants, contrast-enhanced computed tomography showed that the thrombi had decreased.

cyclophosphamide, doxorubicin, vincristine, prednisolone (CHOP) was given on Day 35. A contrast-enhanced CT scan on Day 45 showed that the PE had improved and the thrombus in the descending aorta had disappeared (Figure 3A). The second course of the rituximab and CHOP (R-CHOP) was performed on Day 51, and the patient was discharged on Day 61. Fluorodeoxyglucose-positron emission tomography 6 months after discharge showed that the enlarged lymph nodes around the abdominal aorta and the hyperintensities in the bilateral cervical, axillary, and inguinal lymph nodes had almost disappeared (Figure 3B).

Discussion

With PTLD, or a diffuse large B-cell lymphoma, the risk of a VTE is reported to be 4.8 times higher than in the general population.³ In addition, this patient had taken tacrolimus for more than 1 year after the liver transplantation. Tacrolimus is known to cause TMA. TMA is a thrombotic vascular disorder caused by the formation of platelet thrombi in microvessels from vascular endothelial cell damage due to the calcineurin inhibitory effect of tacrolimus.⁴ This patient showed that ADAMTS13 activity was within normal range, but there were the signs of thrombotic thrombocytopenic purpura (thrombocytopenia, haemolytic anaemia, and kidney disorder), which could suggest that secondary TMA could be the possible diagnosis. Furthermore, thrombosis is reported as a side effect of eltrombopag for thrombocytopenia, with thrombo-embolisms occurring in as many as 6% of patients.⁵ Based on the above, we considered that the systemic thrombosis was caused by a combination of factors, including thrombophilia due to an acutely aggravated tumour and drug-induced thrombophilia.

Because of the possibility of heparin resistance,⁶ we administered fondaparinux, a factor Xa inhibitor, in the acute phase, and switched to apixaban. Although the administration of UFH in the acute phase

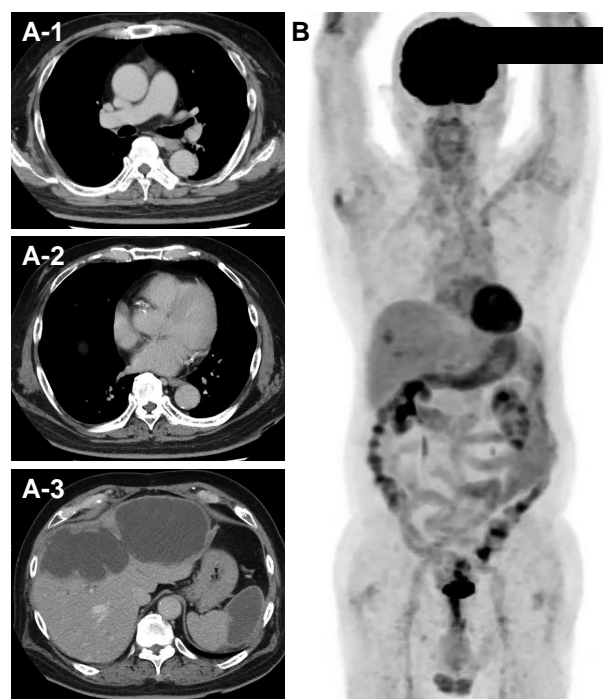


Figure 3 (A) Contrast-enhanced computed tomography on Day 45 showed that the thrombi in pulmonary artery and descending aorta had disappeared; however, a low density area remained in the liver and spleen. (B) A fluorodeoxyglucose-positron emission tomography computed tomography 6 months after multi-disciplinary therapy showed that the hyperaccumulation in the lymph nodes had disappeared.

and warfarin in the chronic phase has conventionally been the major treatment for CAT in Japan, direct oral anticoagulants (DOACs) are recently reported to be effective for CAT. Apixaban was non-inferior to low-molecular-weight heparin in the rate of recurrent VTEs and had a comparable bleeding risk in patients with cancer-associated VTEs.⁷ Although we needed to consider the interaction of drugs such as tacrolimus and doxorubicin with apixaban in this case, we decided to use apixaban at the usual dose because of heparin resistance and severe thrombosis. There was no major bleeding event until discharge, but the measurement of blood levels of apixaban or Xa activity could be a potential option for high-risk patients like the current patient to establish haemorrhagic risk and exclude possible overdosage related to drug interactions.

Since a high amount of thrombi remained even after 3 weeks of anticoagulation therapy, the PTLT activity might have played a significant role in the thrombus formation and treatment of the PTLT was expected to be effective for the thrombosis. However, the risk of a worsening thrombosis due to the chemotherapy itself was of concern.⁸ It seemed to be important to reduce the activity of the PTLT in this patient, and we decided to carefully administer early anticancer drug therapy under anticoagulation. R-CHOP is the most common chemotherapy for DLBCL, but because doxorubicin has been reported to have a thrombosis risk,⁸ rituximab, which has no previous report of thrombosis, was administered in advance, and then a reduced dose of CHOP was added. As a result, the patient successfully achieved both good control of the cancer activity and an improvement in the

thrombosis over the acute stage of the thrombosis. Although the multi-disciplinary therapy for CAT related to PTLT may represent a possible management, further studies are needed to generalize that treatment.

Conclusion

We experienced a case of systemic thromboses including a severe PE due to multi-factors with a rapidly aggravated PTLT, which was successfully treated with multi-disciplinary treatment including anticoagulation therapy and anticancer drug therapy.

Lead author biography



Fumiya Yoneda is a fifth year cardiology fellow at Department of Cardiovascular Medicine, Kyoto University Graduate School of Medicine, Kyoto, Japan. He is interested in thrombosis and arrhythmia.

Acknowledgements

We would like to express our gratitude to Mr John Martin for his grammatical assistance.

Consent: The authors confirm that written consent for submission and publication of this case report including images and associated text has been obtained from the patient in line with COPE guidance.

Conflict of interest: None declared.

Funding: None declared.

Data availability

The data underlying this article cannot be shared publicly due to the privacy of individuals who participated in the study. The data will be shared on reasonable request to the corresponding author.

References

- Abdol Razak NB, Jones G, Bhandari M, Berndt MC, Metharom P. Cancer-associated thrombosis: an overview of mechanisms, risk factors, and treatment. *Cancers (Basel)* 2018;**10**:380.
- Elyamany G, Alzahrani AM, Bukhary E. Cancer-associated thrombosis: an overview. *Clin Med Insights Oncol* 2014;**8**:129–137.
- Walker AJ, Card TR, West J, Crooks C, Grainge MJ. Incidence of venous thromboembolism in patients with cancer - a cohort study using linked United Kingdom databases. *Eur J Cancer* 2013;**49**:1404–1413.
- Nwaba A, MacQuillan G, Adams LA, Garas G, Delriviere L, Augustson B, et al. Tacrolimus-induced thrombotic microangiopathy in orthotopic liver transplant patients: case series of four patients. *Intern Med J* 2013;**43**:328–333.
- Wong RSM, Saleh MN, Khelif A, Salama A, Portella MSO, Burgess P, et al. Safety and efficacy of long-term treatment of chronic/persistent ITP with eltrombopag: final results of the EXTEND study. *Blood* 2017;**130**:2527–2536.
- Levy JH, Connors JM. Heparin resistance - clinical perspectives and management strategies. *N Engl J Med* 2021;**385**:826–832.
- Agnelli G, Becattini C, Meyer G, Muñoz A, Huisman MV, Connors JM, et al. Apixaban for the treatment of venous thromboembolism associated with cancer. *N Engl J Med* 2020;**382**:1599–1607.
- Grover SP, Hisada YM, Kasthuri RS, Reeves BN, Mackman N. Cancer therapy-associated thrombosis. *Arterioscler Thromb Vasc Biol* 2021;**41**:1291–1305.