COMPARATIVE MORPHOLOGY OF THE LUNG WITH SPECIAL REFERENCE TO THE ALVEOLAR EPITHELIAL CELLS

I. LUNG OF THE AMPHIBIA

Yoshio OKADA, Shigetoshi ISHIKO, Shigeo DAIDO
岡田慶夫　石河重利　大道重夫
Jaeha KIM and Sadao IKEDA
金在河　池田貞雄

Surgical Division of the Tuberculosis Research Institute, Kyoto University
(*Director*: *Prof. Chuzo Nagaishi, M.D.*)

(Received for publication February 13, 1962)

Introduction

Since electron microscopic observation of the lung was started in 1952 by Low[9], various investigators have reported the results of their observations. Though all of them agree that the alveolar wall of the mammal is covered by a continuous cellular lining tissue, they are divided in opinion as to the origin of the lining cells.

The authors have attempted to solve this question through comparative morphological studies, that is, through observations not only of the mammalian lung but also of the amphibian, reptilian and avian lung.

The present paper reports the histological and electron microscopic observations of the amphibian lung by the authors.

I. Materials and Methods

Materials used for this study were normal lung tissues of frogs (Rana nigromaculata Hallowell and Bufo vulgaris japonicus Schlegel) and newts (Triturus pyrrhogaster Boié).

The specimens were fixed for one hour at 4°C in 1% osmium tetroxide buffered at pH 7.4 with isotonic phosphate buffer which contained sucrose. After being washed in distilled water and dehydrated in graded ethanol the specimens were embedded in methacrylate.

The sections, cut on a Hitachi microtome model UM-2 or UM-3, were examined with a Hitachi electron microscope model HU-10 or HS-6.

For histological studies, tissues were processed for paraffin block sectioning.

H–E staining, van Gieson's elastic staining and silver impregnation were performed.

II. Results

A. The Lung of Frogs

The lung of frogs has a simpler structure than that of the mammal. Each of the bilateral lungs is spindle shape sack directly connected with the larynx. The internal space of the lung is divided into radial respiratory spaces by many septa as shown in Figs. 1 and 2. Gas exchange is performed in these spaces, but

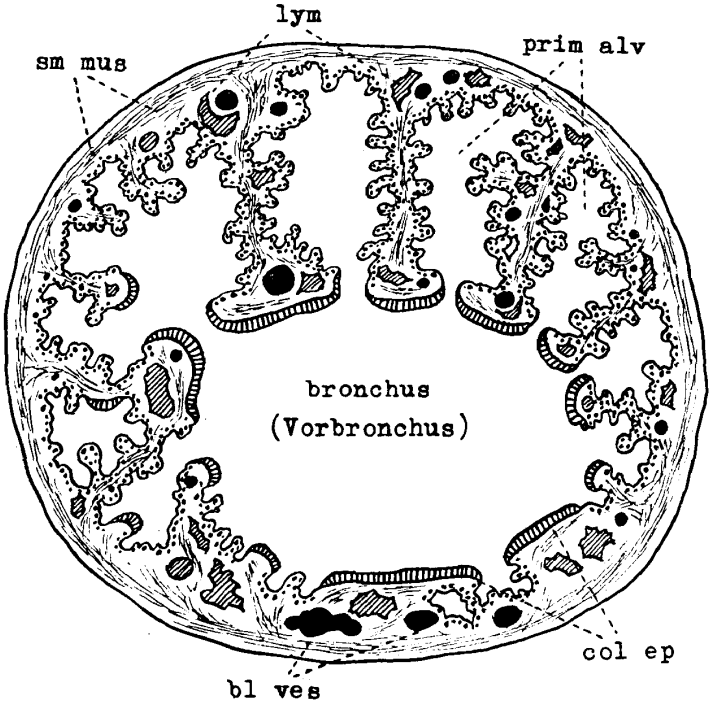

Fig. 1. Primitive alveoli and "Vorbronchus" in the lung of the frog. (schema)
prim alv: primitive alveoli, lym: lymphatics, sm mus: smooth muscles, bl ves: blood vessels, col ep: columnar epithelium.

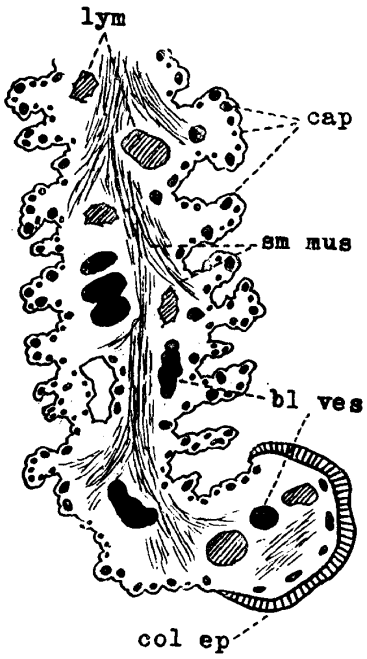

Fig. 2. Alveolar septum of the frog. (schema)
lym: lymphatics, cap: capillaries, sm mus: smooth muscles, bl ves: blood vessels, col ep: columnar epithelium.

they are quite primitive in structure as compared with alveolar space in the mammal. Because of this, the authors call them "primitive alveoli". They join together and form a central lumen which is comparable to the bronchus in the mammal. Marcus[11] (1937) named this structure "Vorbronchus".

1. Histological Findings

The central end of each septum, which is shaped like a club and makes a part of the "Vorbronchus" wall, is covered by a ciliated columnar epithelium which is very similar to the bronchial epithelium in the mammal. Large blood

vessels and prolific muscles are observed there, but a cartilaginous tissue is not seen.

On the surface of the radial septa which face the primitive alveoli, thick capillary networks are observed. Collagen fibers, elastic fibers, smooth muscles, large blood vessels and lymphatics are also found in the interstices of the septa.

2. Electron Microscopic Findings

The wall of the primitive alveolus in the frog is completely covered with a continuous cellular lining, and under this epithelium a thick capillary network is observed. At first sight, it may appear that the epithelial lining of the alveolar wall is composed of one kind of epithelial cell, but close observation reveals that the alveolar epithelial cells can be classified into two groups.

One group is situated on the outer surface of a bulging capillary as shown in Fig. 3. The nucleus is of an elongated oval shape and its long axis lies parallel with the basal membrane as shown in Fig. 4. The thick cytoplasm around the nucleus attenuates abruptly and spreads out in a thin membrane on the surface of the primitive alveolar wall. Numerous microvilli are observed on the surface facing the air space. The nucleus is usually about 5 microns in the long axis and about 2 to 3 microns in short axis. This cell is very similar to an epithelial cell which is called "alveolar epithelial cell" (Itagi), "type A epithelial cell" (Yasuda) and "small alveolar cell" (Policard et al.) in the mammal.

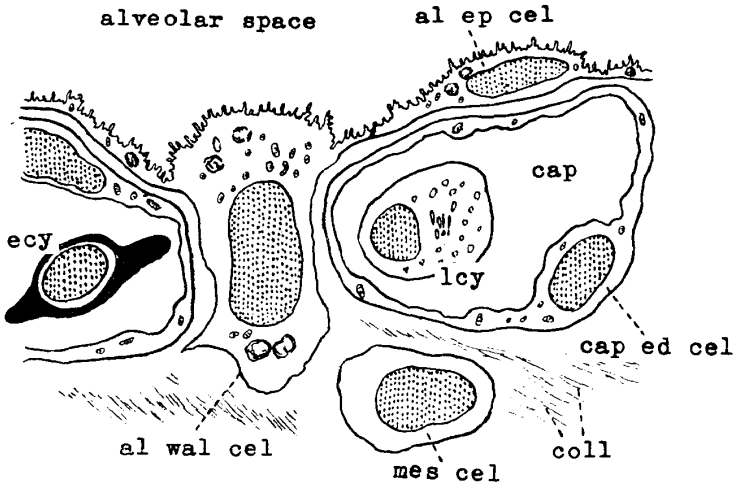

Fig. 3. Fine structure of the alveolar wall in the lung of the frog. (schema)
al ep cel : alveolar epithelial cell,
al wal cel : alveolar wall cell,
cap : capillary lumen,
cap ed cel : capillary endothelial cell,
ecy : erythrocyte, lcy : leucocyte,
mes cel : mesenchymal cell, coll : collagen fibers.

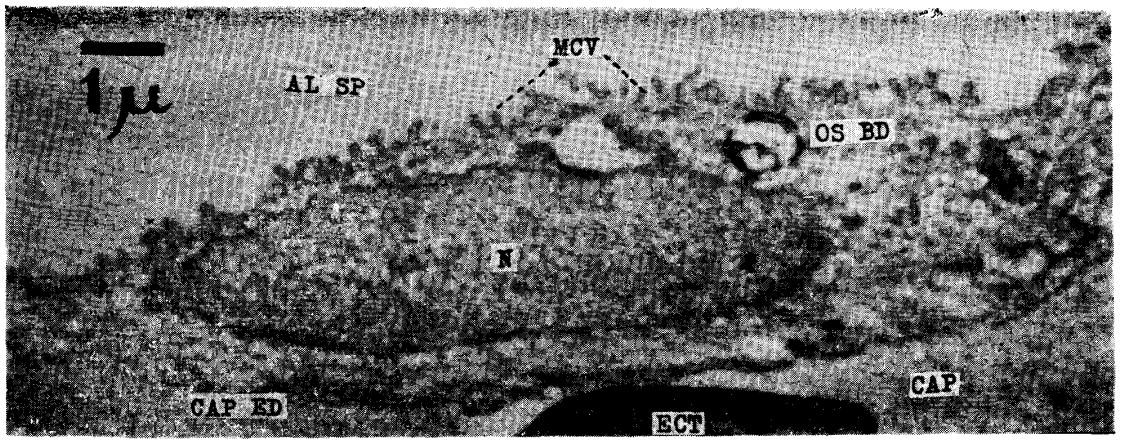

Fig. 4. Alveolar epithelial cell of the frog.
AL SP: alveolar space, CAP: capillary lumen,
CAP ED: capillary endothelium, ECT: erythrocyte,
MCV: microvilli, OS BD: osmiophilic body, N: nucleus.

Special organelles with a strong affinity for osmium which are called osmiophilic bodies (Policard et al.), Cytoplasmapartikel (Schlipköter), Plasmasome (Kisch) or osmiophile Einschlüsse (Bargmann et al.) are often found in this cell as shown in Fig. 5.

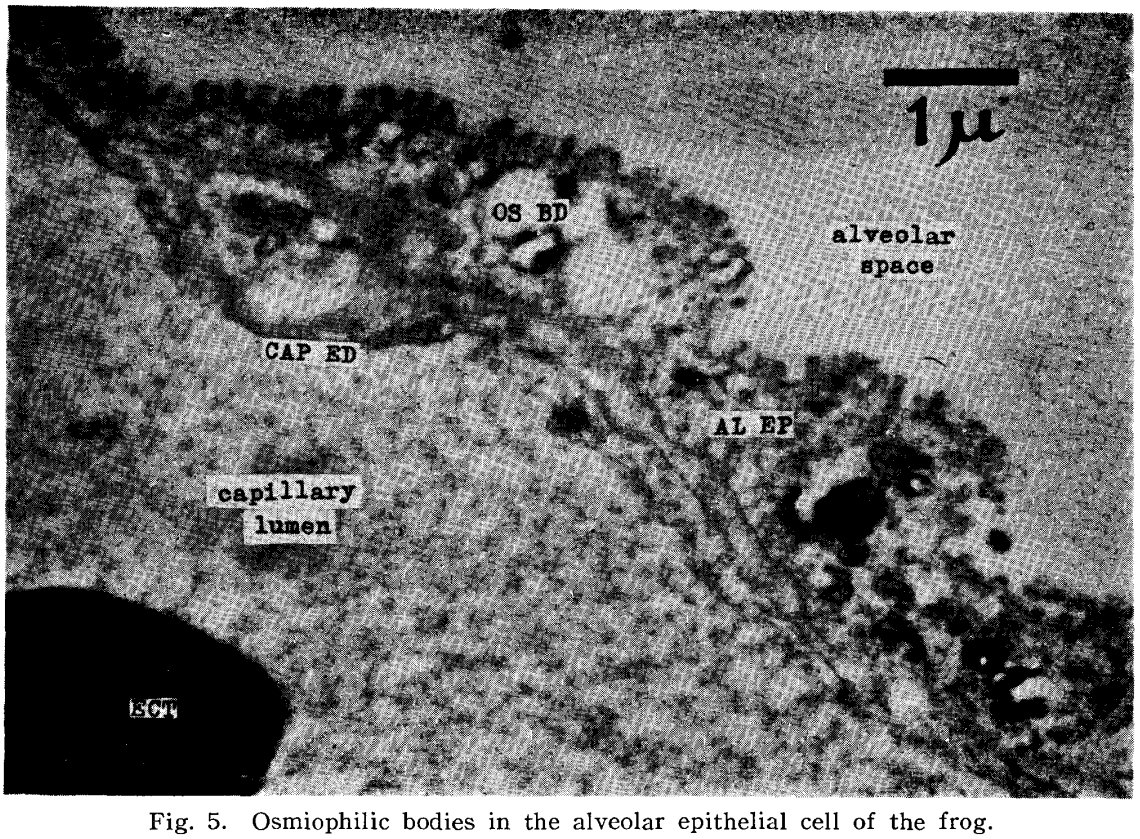

Fig. 5. Osmiophilic bodies in the alveolar epithelial cell of the frog.
OS BD: osmiophilic body, AL EP: alveolar epithelial cell,
CAP ED: capillary endothelial cell, ECT: erythrocyte.

Another group of epithelial cells in the alveolar area is usually of oblong shape and situated in the niche between ajacent capillaries as shown in Fig. 6. The nucleus is ovoid shape, and sometimes has deep indentations and irregularities in its contour. The long axis of the nucleus is about 6 microns. Mitochondria

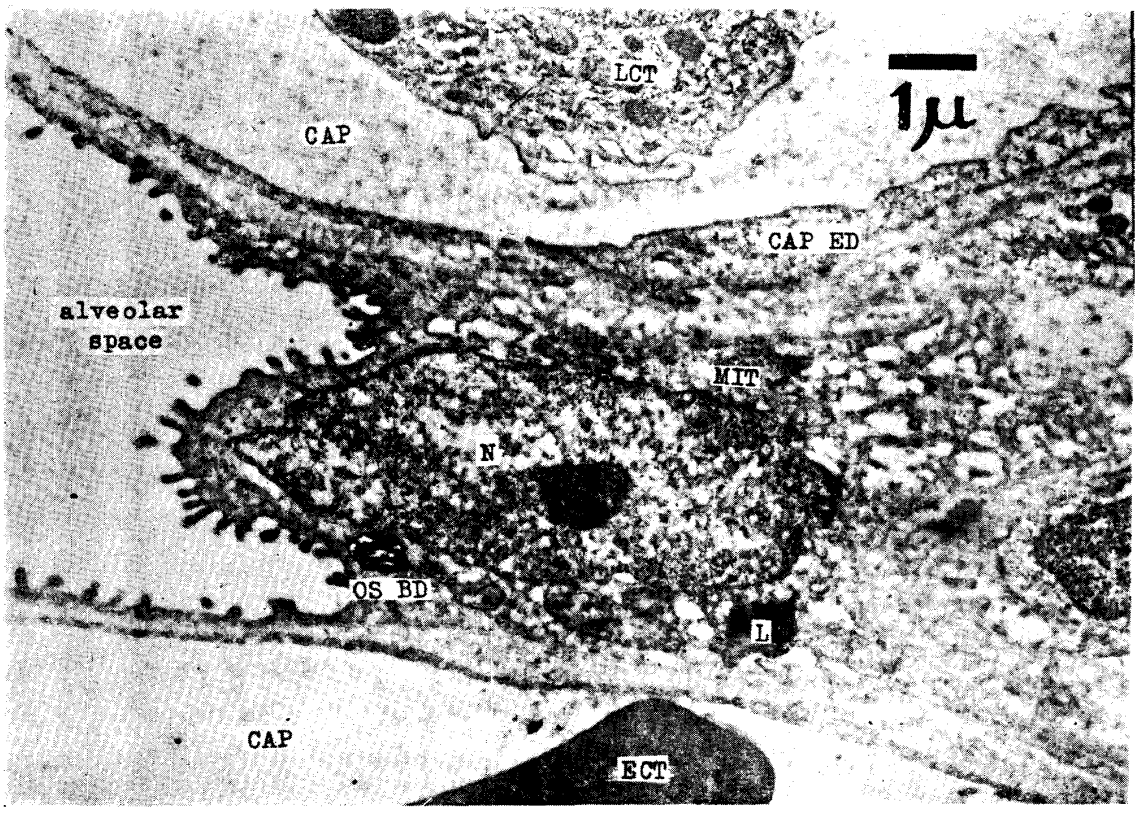

Fig. 6. Alveolar wall cell of the frog.
CAP: capillary lumen, CAP ED: capillary endothelivm,
ECT: erythrocyte, MIT: mitochondria, L: liposome,
OS BD: osmiophilic body, N: nucleus.

and endoplasmic reticula are abundantly distributed in the cytoplasm. Osmiophilic bodies are found to be more plentiful than in the "alveolar epithelial cell". A large number of microvilli are observed on the surface facing the air space. Since these findings are similar to those of "alveolar wall cell" (Itagi), "type B epithelial cell" (Yasuda) and "large alveolar cell" (Policard et al.) in the mammal, the authors prefer to call this cell the "alveolar wall cell" in the amphibia. In contrast with the mammal, the cytoplasm of the "alveolar wall cell" of frogs spreads out and covers the alveolar wall in the same way as the "alveolar epithelial cell".

The thinnest part of both of the two kinds of epithelial cells in the alveolar area measures about 0.1 to 0.2 microns thick as shown in Fig. 7. The basement

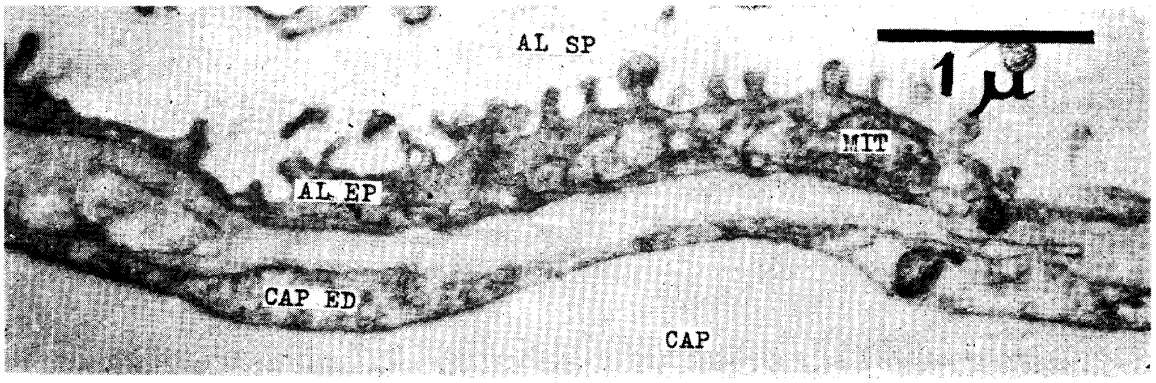

Fig. 7. Air-blood-barrier in the lung of the frog.
AL SP: alveolar space, AL EP: alveolar epithelial cell,
CAP ED: capillary endothelial cell, MIT: mitochondria.

membrane of these epithelial cells is homogeneous and about 150 Å in thickness. The cytoplasm of endothelial cells of the alveolar blood capillary has greater density than that of epithelial cells, and extends as a thin membrane in the same way as in the alveolar epithelial cell. Therefore, the blood in the alveolar capillary is in contact with the alveolar air space through a very thin layer of cytoplasm, and the entire blood-air-pathway, that is the epithelial cell, endothelial cell and basement membranes of both cells, is approximately 0.3 to 0.7 microns thick.

B. The Lung of Newts

The newt has a pair of tubular lungs. They join with each other at the oral end where they connect with the larynx. No septum is seen in the interior of the lung.

1. Histological Findings

Some parts of the internal surface are covered with a columnar ciliated epithelium as shown in Fig. 8. Cartilage cannot be found anywhere in the lung. Although the lung of newts is much simpler in its structure than that of frogs, and has only a simple air space, the authors would like, for the convenience of description, to call the internal space of the lung "primary alveolus" as was done in the case of frogs.

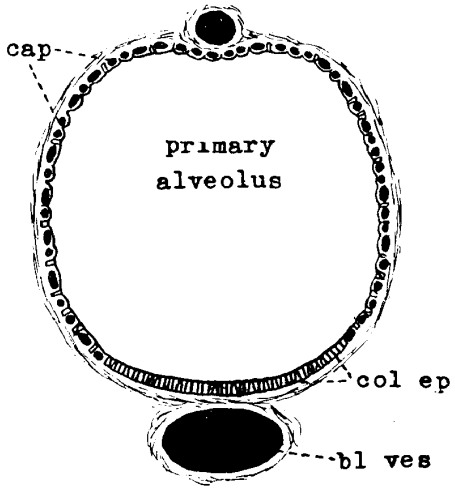

Fig. 8. Lung of the newt. (schema)
cap: capillaries,
col ep: columnar epithelium,
bl ves: blood vessel,

2. Electron Microscopic Findings

The epithelial lining cells are classified into two groups similar to those of frogs. One group is situated on the surface of capillaries and the other is situated in the niche between capillaries as shown in Fig. 9. The shapes and the cytoplasmic structure of the former are very similar to those of the alveolar epithelial cells in frogs except for the lack of osmiophilic bodies as shown in Fig. 10. And those of the latter are also very similar to the "alveolar wall cells", but osmiophilic bodies in their cytoplasm were not seen as shown in Fig. 11.

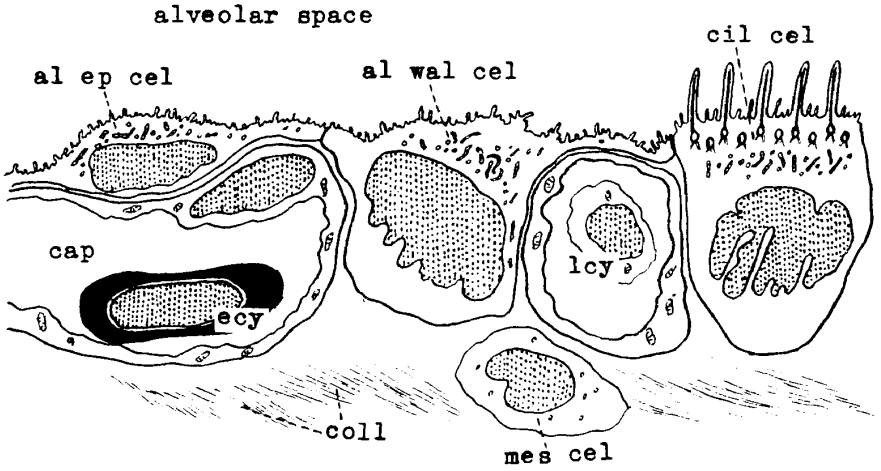

Fig. 9. Fine structure of the alveolar wall in the lung of the newt. (schema)
al ep cel : alveolar epithelial cell, al wal cel : alveolar wall cell, cil cel : ciliated cell, cap : capillary lumen, ecy : erythrocyte, lcy : leucocyte, mes cel : mesenchymal cell, coll : collagen fibers.

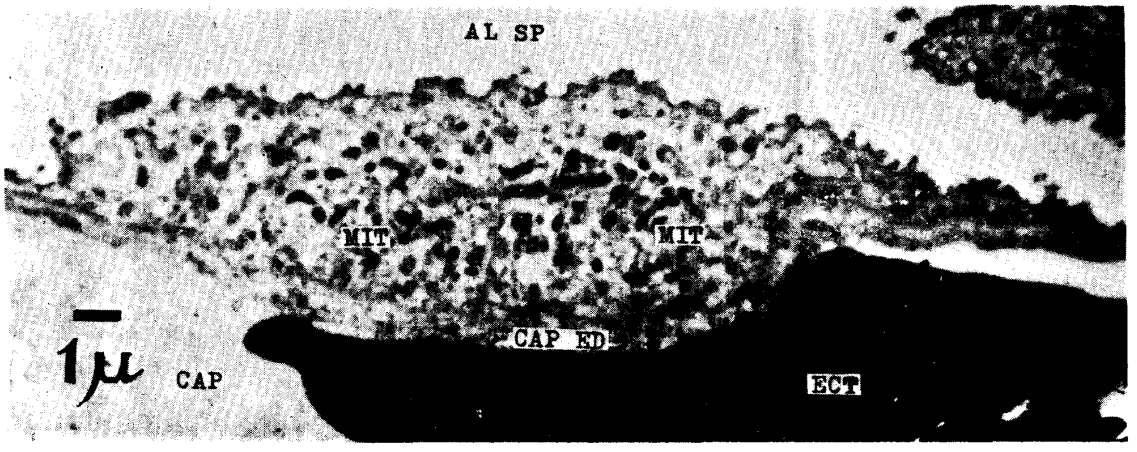

Fig. 10. Alveolar epithelial cell of the newt.
AL : alveolar space, CAP ED : capillary endothelium, CAP : capillary lumen, ECT : erythrocyte, MIT : mitochondria.

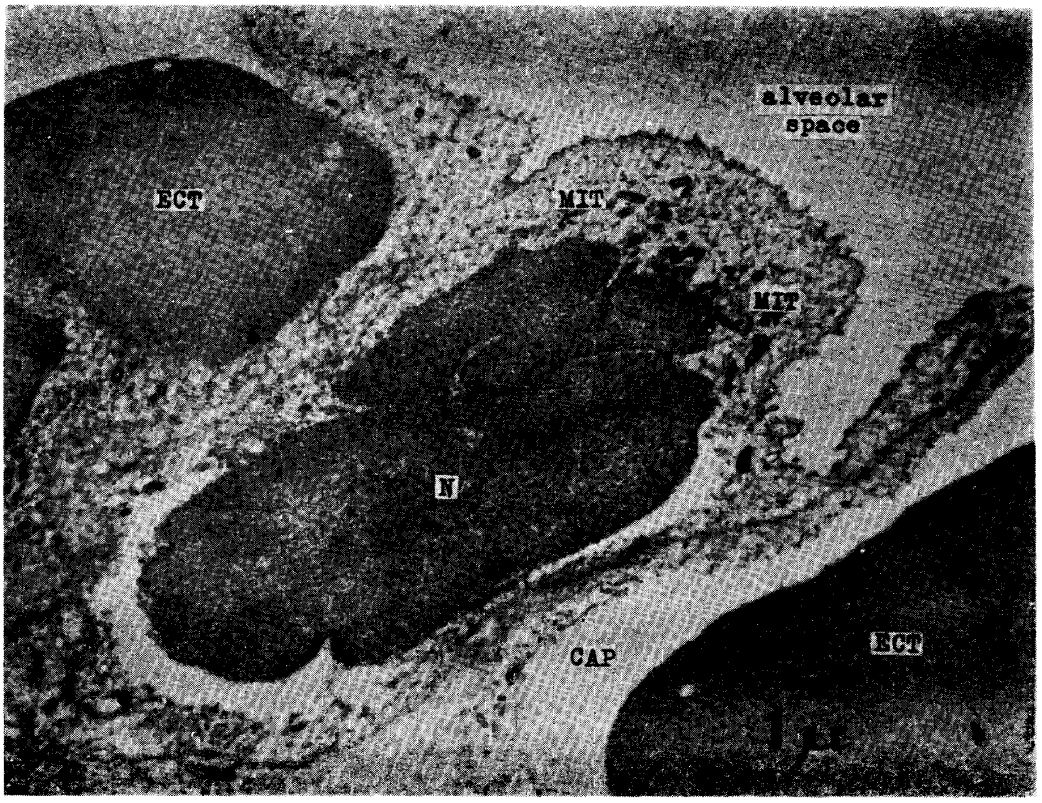

Fig. 11. Alveolar wall cell of the newt.
ECT : erythrocyte, CAP : capillary lumen,
MIT : mitochondria, N : nucleus.

Besides the alveolar wall cell, ciliated cells in the niche between ajacent capillaries, which resemble bronchial ciliated cells in mammalia were often observed.

III. Discussion

The amphibia has the simplest and the most primitive lung structure among vertebrates. Especially in the case of the newt, that lives almost whole its life under water, the lung is no more than a simple air sack of a tubular form. The lung of the newt appears to work not only as a respiratory organ but as a static organ like the air-bladder of fishes. Gas exchange can be performed, but insufficiently, through poorly distributed capillaries on the inside of the lung.

The frog, living mostly on land, has a fairly well developed lung, made up of finely divided respiratory spaces and copiously distributed capillary networks, so that gas exchange is more efficient than in the newt. The "Vorbronchus" in the frog is a primitive bronchus, and shows differentiation of the bronchus and alveolus.

By electron microscopic observation, the existence of a continuous epithelial lining on the alveolar wall in the amphibia comparable to that which exists in

the mammalia was shown. However, the epithelial lining tissue of the amphibian lung has some difference when compared with that of the mammalian lung.

The cells which compose the continuous epithelial lining of the mammalian lung are classified into two types. Following Itagi's steps, the authors have called them the "alveolar epithelial cell" and the "alveolar wall cell". Each of these two types of cells has very characteristic structures. That is, the "alveolar epithelial cell" stretches out a lateral cytoplasmic extension and covers the alveolar wall, but has no osmiophilic bodies. On the other hand, the "alveolar wall cell" has no cytoplasmic extension but possesses osmiophilic bodies in the cytoplasm. In mammals, osmiophilic bodies are not found in any other tissue or organ and are therefore thought to be characteristic of the "alveolar wall cell".

The origin of the "alveolar wall cell" in the mammal is thought by some to be epithelial and by others to be mesenchymal. The reason why it is thought to be of mesenchymal origin is that the "alveolar wall cell" of the mammal appears to be so difference in structures from the "alveolar epithelial cell", and that some of the "alveolar wall cells" resemble so-called dust cells in the air space which is presumed to be of mesenchymal origin.

In the frog, the alveolar epithelial cell is flatter than the alveolar wall cell and is found not in the niche between capillaries but on the outer surface of a bulging capillary. However, these two kinds of epithelial cells in the frog resemble each other in that they both have microvilli, osmiophilic bodies and membraneous extension of cytoplasm. In the newt, these two kinds of epithelial cells are devoid of osmiophilic bodies in their cytoplasm but resemble each other in their fine structure. It may be ascertained that these facts are clear evidence of the same epithelial origin of both types of cells.

As to absence of osmiophilic bodies in the newt, we can assume that these bodies are highly developed organelles in the cytoplasm and are not found in the newt which has one of the lowest forms of vertebrate lung.

Summary

Comparative morphological study on the lung of the frog and newt was made leading to the following conclusions:

1) The lung of the newt is the simplest among vertebrates and seems to work not only as a respiratory organ but also as static organ.

2) In the lung of the frog, the "Vorbronchus", which serves as a passage for air, and the "primitive alveoli", in which gas exchange is performed, are fairly well differentiated.

3) In the mammalian lung, the "alveolar epithelial cell" is often assumed

to be of mesenchymal orgin. However, in the amphibian lung, the "alveolar wall cell" resembles the "alveolar epithelial cell", and it may be ascertained that the "alveolar wall cell" is of epithelial origin.

4) Osmiophilic bodies are found in the "alveolar wall cell" and in the "alveolar epithelial cell" of the frog, but not in those of the newt. It is assumed that these bodies are highly developed organelles, and therefore, are not found in the newt which is one of the lowest forms of vertebrates with lungs.

REFERENCES

1) Bargmann, W. and Knoop, A.: Ztschr. Zellforsch., **44**: 263, 1956.
2) Itagi, K.: Acta Tuberc. Jap., **6**: 75, 1956.
3) Itagi, K.: Acta Tuberc. Jap., **6**: 91, 1956.
4) Karrer, H. E.: J. Biophys. Biochem. Cytol., 2 (suppl.): 115, 241 & 287, 1956.
5) Karrer, H. E.: Bull. Johns Hopkins. Hosp., **98**: 65, 1956.
6) Kikuth, W., Schlipköter, H. W. and Schroeter, P.: Electron Microscopy, edited by Sjöstrand and Rhodin, Almqvist & Wiksell, Stockholm, 1957.
7) Kisch, B.: Exp. Med. & Surg., **13**: 101, 1955.
8) Low, F. N.: Anat. Rec., **113**: 437, 1952.
9) Low, F. N.: Anat. Rec., **117**: 241, 1953.
10) Low, F. N.: Anat. Rec., **120**: 827, 1954.
11) Marcus, H.: Lungen in Handb. d. vergleich. Anatomie d. Wirbeltiere, Urban & Schwarzenberg, Berlin and Wien, 1937.
12) Nagaishi, C. and Okada, Y.: Acta Tuberc. Jap., **10**: 20, 1960.
13) Policard, A., Collet, A. and Giltaire-Ralyte, L.: Presse méd., **62**: 1775, 1954.
14) Policard, A., Collet, A. and Giltaire-Ralyte, L.: Compt. Rend. Acad. Sci., **240**: 2363, 1955.
15) Policard, A., Collet, A. and Pregermain, S.: in Electron Microscopy, edited by Sjöstrand and Rhodin, Almqvist & Wiksell, Stockholm, 1957.
16) Schlipköter, H. W.: Dtsch. med. Wochschr., **79**: 164, 1954.
17) Schulz, H.: Beitr. path. Anat. u. allg. Path., **119**: 45, 1958.
18) Schulz, H.: Beitr. path. Anat. u. allg. Path., **119**: 71, 1958.
19) Schulz, H.: Die submikroskopische Anatomie und Pathologie der Lunge, Springer Verlag, Berlin, 1959.
20) Swigart, R. H. and Kane, D. J.: Anat. Rec., **118**: 57, 1954.
21) Yasuda, H.: Acta Path. Jap., 8: 189, 1958.