

Tissue Reactions Induced by Solid Proteins

Hideo TAKAMATSU, Akira MIZUTANI, Koichi YOKOTA and Masashi AMATSU*

*From the Pathological Division (Chief: Hideo TAKAMATSU) of the
Tuberculosis Research Institute, Kyoto University.*

(Received for publication August 27, 1955)

Introduction

When any tissues are injured, as is well known, necrosis may result at the site of the injury in the tissues. Although there are many causes of necrosis, we can classify them into non-infectious such as physical or chemical stimuli or insufficiency of blood supply, and infectious, due to microorganisms.

The necrotic tissue seems to be not only useless but even a foreign substance for the individual; so an excluding mechanism will appear. During removal of this necrotic tissue, liquid material is absorbed easily but in the case of solid material so called organization will occur. These phenomena have been investigated already by many pathologists. The necrotic tissue is regarded as a foreign substance. The term "foreign" ordinarily includes two meanings; the first is a solid phase and the second is serological differentiation from that specific for the living body. The liquid substance will be absorbed from the necrotic area and digested in some other organs. The solid substances are seen in coagulation necrosis such as tuberculous caseation and in many infarctions. These coagulated necrotic substances can be absorbed too, but the mechanism is not so clear in detail. Whatever the cause of necrosis may be, it is certain that the necrotic mass will consist of a mixture of proteins and various other substances. Many investigators have thought that the caseous substances are hardly absorbable but we are sure that they are. How are they absorbed? What kinds of cells take part in cellular digestion in what way? Are there any differences in the mechanism of absorption of various proteins? These points are not clear. If these problems are solved, that knowledge will serve to clarify various pathological changes. We investigated the histological reactions induced by some well known solid proteins.

Experiment

Experiment I.

As foreign proteins, egg white, egg albumin, globulin, casein and gelatin were used. These proteins were inserted into the subcutis of albino rats weighing about 120 g.; that is, egg white and albumin, being coagulated by heat, were injected into the sub-

* 高松英雄, 水谷 昭, 横田耕一, 天津 正

cuits by syringe and needle, and the others were directly inserted by cutting the skin, because of insolubility in water or of not being coagulated by heat. This was done as aseptically as possible. Then 2 hours, 3 hours, 5 hours, 10 hours and every day for 7 days after insertion, histological investigation was done with hematoxylin-eosin stain, Van Gieson's stain, Mallory's connective tissue stain and proteolytic ferment stain by Takamatsu's method.^(8,9,10)

Experiment II.

The second experiment was performed to compensate for the faults of the first experiment in which three proteins, globulin, casein and gelatin, were inserted into the subcutis of albino rats by cutting the skin; the inserted amounts were not determined.

The second experiment was performed as follows: A small amount of each protein (albumin, globulin and casein) which had been powdered in the mortar and sterilized by dry heat (100–120°C) for 15–20 minutes, was packed in the tip of a trocar. Then, these substances were injected into the subcutis of albino rats directly. This method is free from the influence of the insertion itself, and the amounts injected can be determined.

The histological reactions in the subcutis of rats at 1, 3, 5 and 7 days after insertion were investigated by the same staining methods as in the first experiment. The results are as follows.

Results

Experiment I.

1) *The reactions to egg white.*

The manifestation of reaction to egg white in the subcutis of rats is seen already 2 hours after insertion. Blood vessels dilate and numerous polymorphonuclear leukocytes migrate, especially neutrophils. These leukocytes increase in number gradually and even invade crevices in the egg white and phagocytize it. The attraction of polymorphs is most conspicuous 1 day after insertion, then they decrease in number gradually and are scarcely seen on the 5th day. From 10 hours to 2 days after insertion, some leukocytes, with small and rather round nuclei, are found. They are regarded as a degenerative form of polymorphs. Mononuclear cells begin to migrate after 5–10 hours following the polymorphs; the round or oval nucleus is relatively larger and the cytoplasm is better defined than that of polymorphs. These cells move not only into the surrounding tissue but even into the crevices of the egg white. These cells show greater penetration and phagocytosis than the polymorphs.

2 or 3 days later, these cells enlarge with phagocytosis; in the nucleus chromatin concentrates on the nuclear membrane and protoplasm is deformed and extends into the white mass. Mitosis in these cells is found just near the white or even in the crevices. The mononuclear cells, macrophages, multiply and are more active in the functions of migration and phagocytosis than the polymorphs. Pyknosis and karyorrhexis of cells, probably polymorphs, are seen in the crevices.

On the 3rd day, 20 or more round or oval, pale staining nuclei get together near the egg white. This is probably the beginning of the formation of a giant cell. At the same time, many cells form long oval or rod shaped, pale staining nuclei like epithelioid cells, but their protoplasm is more clearly defined than that of epithelioid cells. They are regarded as macrophages, too.

On the 4th and 5th days, there are various formed cells and most of them are macrophages; 1) cells with rather round, relatively small (but larger than those of polymorphs) and not such pale nuclei, with well defined eosinophilic protoplasm; these are probably monocytes that do not yet phagocytize very much; 2) as already stated, cells with oval, long oval, bottle shaped or even rod shaped pale-staining nuclei; these are macrophages digesting the egg white; 3) cells with large, oval or bottle-shaped, paler staining nuclei, the protoplasm very large and rather basophilic; they are believed to be macrophages deformed by marked phagocytosis. Some of 2) and 3), especially of the latter, suggest the existence of ingested protein in their protoplasm. In addition, there are degenerating cells, mulberry-shaped, well-staining and even karyorrhectic nuclei, and vacuoles in their protoplasm, but these are not numerous.

Other wandering cells, such as polymorphs and lymphocytes are very rare. In this stage, the cellular reaction is restricted to the surrounding connective tissue layer and hardly spreads beyond it. Vascular changes exist in the outer layer, but there the reaction is weak generally. In some of these vessels, it is interesting that nuclei of endothelial cells are round or cubic and project into the internal vascular lumen. The connective tissue layer consists of originally existing loose connective tissue, proliferating fibroblasts and fine collagenous fibers. The proliferation of fibroblasts and production of collagenous fibers are found after the 3rd or 4th day. The fibroblasts are rather elongated and bipolar in earlier days, but large asteroid fibroblasts with collagenous fiber-like projections are found a few days later. The new collagenous fibers are differentiated from preexisting fibers by their more delicate structure and paler staining with Van Gieson's stain.

On the last day, the 7th day, egg white undergoing phagocytosis forms complicated hollows with many cells along the edge and some particles are isolated and surrounded by many cells (macrophages and fibroblasts). In some areas, there are groups of macrophages surrounding a very small amount of egg white, and groups without fibroblasts or collagenous fibers and no egg white left. This suggests complete phagocytosis.

In general, macrophages of various shapes, which have already been described, are predominant as types of migrating cells, especially monocytes; there are few polymorphs and lymphocytes and almost no plasma cells.

Fibroblasts proliferate even very near the egg white and large asteroid or lozenge-shaped fibroblasts exist in the connective tissue layer at a short distance from the egg white. Connective tissue staining shows the fibroblasts invading the crevices of egg white with collagenous fibers. Giant cells of the foreign body type are found in the surrounding connective tissue layer. At the most typical one, over 30 nuclei, which were round or oval, pale or well staining, scattered irregularly in eosinophilic protoplasm. It

does not resemble a Langhans giant cell.

The reactions to egg white are generally mild.

2) *The reactions to albumin.*

Albumin, inserted in the subcutis of rats, causes inflammation already 2 hours after insertion: vascular dilatation, cellular migration, especially of polymorphonuclear leukocytes. The polymorph-migration is stronger and more prolonged than in the case of egg white. Many polymorphs which have penetrated into the crevices degenerate. Many fragments of destroyed nuclei are found there.

On the 2nd or 3rd day, most of the migrating cells are polymorphs too, with a few macrophages. Proliferation of fibroblasts is observed in the surrounding area; fibroblasts are bipolar rather than multipolar or asteroid and not so large. The large basophilic fibroblasts, which are numerous in the case of egg white, are rare. Moreover, the formation of capillary vessels at the outer edge of the fibroblast-layer is seen; that is, the formation of granulation tissue. This granulation tissue grows more thickly with the lapse of time. Polymorphs, macrophages and a few lymphocytes exist in it.

Polymorphs diminish in number gradually and most of the cells are not polymorphs but fibroblasts and macrophages in granulation tissue and they invade the albumin on the 7th day.

No giant cells are found anywhere.

3) *The reactions to globulin.*

Globulin, as a source of inflammation, causes an intense reaction. The polymorph-migration is very conspicuous and precipitation of fibrin is also marked. The particles of globulin are surrounded by many polymorphs and a thick fibrin and connective tissue-layer. Many of these cells have degenerated and many fragments of destroyed nuclei are scattered. There are very few cell elements in the fibrin-layer. Marked swelling of the endothelial cells of the blood vessels is seen even in the muscle layer far from the globulin on the 2nd day. Polymorph-migration grows more intense with the lapse of time, and macrophages are few. Striking formation of granulation tissue is found in the outer layer, and the particles of globulin are separated from this granulation tissue by the above-mentioned fibrin-layer. This granulation tissue is much thicker and closer than that caused in reaction to albumin.

On the last day, 7th day, most of the migrating cells are polymorphs and macrophages, and most of the globulin is isolated and a few particles are encapsulated by connective tissue and have been somewhat digested by phagocytic cells. No giant cells are found on any day.

4) *The reactions to casein.*

Casein induces reactions similar to those induced by globulin, i. e. vascular stagnation, exudation of fibrin, and cellular migration, most by polymorphs at an early stage. On the 3rd and 4th days, however, the edges of the particles of casein form irregular

indentations containing some polymorphs, showing phagocytosis by these cells. It is inferred that casein is easily digestible by polymorphs (this was not found in the case of globulin).

On the 4th and 5th days, the reactions are differentiated into 4 layers; from the center outwards: 1) casein, 2) polymorphonuclear leukocyte layer, 3) fibrin layer containing some polymorphs and other cells, and 4) granulation tissue layer. Layer 2 consists of numerous polymorphs and surrounds the casein as a dense but not thick wall of cells. Some of these cells invade the casein as was stated already. Many cells are degenerating and many fragments of destroyed nuclei are found here. Layer 3 is a structureless or a fine fibrinous eosinophilic layer, and cells are few. This layer is clearly differentiated from layer 2. The outer most granulation tissue layer is similar to that in the reaction to globulin.

On the last, 7th, day, the casein is almost completely digested and surrounding of it is the fibrin layer; these two layers contain mostly degenerating cells, but the polymorph-layer (which was seen on the 4th and 5th days) is not differentiated as a layer. The granulation tissue has proliferated further in the outermost layer. The inside two layers are usually clearly separated from the granulation tissue.

5) *The reactions to gelatin.*

Gelatin dissolved and formed a sticky fluid 2-3 hours after insertion, as it is soluble in water, and was not clearly demarcated from the surrounding tissue.

Gelatin also induces migration of polymorphonuclear leukocytes at an early stage. Numerous polymorphs migrate diffusely and phagocytize the dissolved gelatin; i.e., numerous polymorphs are found in the homogeneously dissolved gelatin forming round vacant spaces in the surrounding area by phagocytosis, in hematoxylin-eosin stained specimens.

The degree of migration is much greater than in the case of egg white but not so great as in the case of globulin and casein.

The migration of mononuclear cells (histiocytes and monocytes) is seen starting on the 2nd or 3rd day, and they are rather more numerous than polymorphs by the 5th day. On the 5th day, most of the liquidified gelatin has disappeared due to cellular digestion or engulfing and the area is filled with fibrin, fine connective tissue, and cell-elements (chiefly histiocytes and monocytes; polymorphs are relatively few, and lymphocytes and plasma cells are almost negligible).

On the last, 7th, day, there is still a little undissolved solid gelatin but, unlike globulin, it does not collect many polymorphs. The liquid gelatin is invaded by cells and connective tissue. The cell-elements resemble those which invade egg white.

Formation of granulation tissue is observed by the 4th or 5th day but is not very conspicuous. Giant cells are not found.

*Experiment II.*1) *Albumin*

24 hours after insertion, the thick layer of polymorphonuclear leukocytes around albumin is most conspicuous and numerous polymorphs are gathered densely. Macrophages and fibroblasts are found in the outer region, and the blood in neighboring vessels stagnates.

On the 3rd day, some small granules of albumin on the outer side are suffering from phagocytosis by polymorphs and form irregular hollows. Large or small variously shaped fibroblasts are found in the outermost layer, especially large asteroid forms with rather basophilic protoplasm which sometimes contains vacuoles, the nuclei are round or oval, large, and pale staining.

On the 5th and 7th days, the number of polymorphs is greatly diminished in the polymorph-layer, but the macrophages and fibroblasts increase. Connective tissue stain shows many fine collagenous fibers extending irregularly into this layer, in a rather centripetal direction, and other large collagenous fibers surround this layer. The border between this layer and the outermost layer is clear. Most of the cells in the outermost layer are composed of fibroblasts and macrophages. Other cells, such as lymphocytes and plasma cells, are almost negligible. Very little albumin remains.

2) *Globulin.*

Numerous polymorphs gather around the globulin and their compactness is denser than around the albumin. The density reaches a maximum on the 3rd and 5th days, but phagocytosis by these cells is slight, and they have a strong tendency to degenerate.

On the last, 7th, day polymorphs diminish in number and macrophages and fibroblasts increase. The gathering of fibroblasts is conspicuous in the outermost layer, and they invade the inner layer. Collagenous fibers are dense in the surrounding areas but are not found in inner layer so much as in the case of albumin.

3) *Casein.*

The reactions to casein resemble those to albumin. The migration of polymorphs, followed by their substitution by macrophages and fibroblasts and the production of collagenous fibers are found, too, but they are very mild and most of the inserted substance has been digested by the last day.

As above mentioned, no specific differences between the reactions to each kind of protein were found. That is, they all have a dense polymorph-layer surrounding the protein, then these cells are replaced by macrophages and fibroblasts. The outermost layer, most of the cells of which are proliferated and proliferating fibroblasts, is separated from the inner layer by collagenous fibers. But the degree of conglomeration of cells is somewhat different in each case, and collagenous fibers are compact in the outside layer but scarcely seen in the inside layer in the case of globulin which is digested only with difficulty.

Comments

The investigation of the histological reactions in the subcutis of albino rats to solid proteins (egg white, albumin, globulin, casein and gelatin) results in the conclusion that no fundamental differences exist between the reactions to the various proteins.

The reactions are divided, in general, into vascular changes, migration and phagocytosis by polymorphonuclear leukocytes and macrophages, and proliferation of fibroblasts and production of collagenous fibers.

The reactions are considered to be most mild in the case of egg white. Polymorphs migrate early and the transitory vascular changes occur before the migration of polymorphs; dilatation of vessels and stagnation of blood are found and partial migration of polymorphs through the vascular wall is seen. This change probably belongs to the phase 4 of Clark.⁽¹⁾ Clark et al. classified the vascular change into six phases by their experiments on living amphibian larvae and by transparent chambers inserted in rabbit's ears. It is impossible to study the vascular changes in detail by fixed and stained specimens as in our experiments, but it can safely be said that the permeability of the vascular wall increases following the insertion of proteins, and is accompanied by migration of cells.

Other proteins also induce early migration of polymorphs through the vascular wall, but the degree of reactions is stronger than in the case of egg white.

It is of interest that endothelial cells of blood vessels swell and even project into the lumen in some specimens of egg white and globulin reaction, especially in the latter. This was not found with other proteins. Spector⁽²⁾ has reported that polypeptides with an average chain length of 8-14 amino acid residues produced by enzymatic digestion of protein induced polymorph migration from the vessels and caused the vascular endothelium to swell. As to polymorph migration, it occurs more quickly and in greater numbers than that of other leukocytes regardless of the character of the inciting stimulus. This will be discussed later. As to the endothelial swelling, only globulin and egg white, which contains a small amount of globulin, caused endothelial swelling in our experiment. If Spector's finding is accepted, it is believed that three kinds of proteins are easily digestible and quickly disintegrate to lower polypeptides or amino acids, so they do not stimulate endothelium to swell. Only globulin retains high enough polypeptides to cause endothelial swelling because it is hard to digest (the digestibility of proteins will be discussed later). This is still under investigation. This problem is interesting in regard to antigen-antibody reaction since a component of antibody is in gamma globulin and the reaction can cause endothelial swelling.

A large collection of polymorphs is found early around each of proteins. Polymorphonuclear leukocytes are the dominant type of migration cells early in these experiments regardless of the character of the external stimulus, but it is noted that differences in degree of response exist. Although the migration of polymorphs out of vessels generally ceases 1-3 days after insertion, the reactions are mildest in the case of egg white,

strongest in globulin, and moderate in albumin, gelatin and casein. In the case of egg white, the number of these cells close to the substance is maximum 24 hours after insertion and then diminishes gradually and they are scarcely seen after the 4th day. However, polymorphs attracted by globulin form a dense cell-wall around the substance and are liable to degenerate. In the second experiment, the reaction to globulin is milder than that in the first experiment but stronger than that to other proteins.

The reactions of the second experiment are much milder those of the first one. This is natural considering the method of insertion. Further research has shown that small, irregular cells with pale staining irregular round or oval nuclei increase gradually in number around egg white after 5 hours. They may belong to the category of "round cell infiltration" but they are not other leukocytes but degenerative forms of polymorphs. The present authors incline to the same opinion of "rounding up" as Clark et al.^(1, 3, 4, 5) in regard to these cells. Moreover, according to their investigation, the polymorph response to small injections not only of protein also of any other foreign body is so slight quantitatively and temporally as to be almost negligible. But our investigations supply no data whatever in regard to this problem.

The above mentioned response should be classified as an early reaction.

The later reaction is as follows. The polymorphs gradually diminish in number and the macrophages increase. (Here the term of macrophage is used, according to Anderson, as the large phagocyte of Metchnikoff, so it includes histiocytes, monocytes, etc.. It is impossible to differentiate these cells exactly in our experiments). Some of them migrate out of blood vessels by the same mechanism as polymorphs which are numerous early. Monocytes and histiocytes migrate around the injected egg white and, moreover, mitosis of these cells is observed close to the edge of the egg white or even in its crevices. This indicates that wandering cells not only migrate from vessels or surrounding tissue but also proliferate in the injured area.

Macrophages at early stages —2 or 3 days after injection—are round or oval; their protoplasm is better defined and larger than that of polymorphs, and their nuclei are round or oval, nonlobed but often indented, and not so pale staining. But some of them are difficult to differentiate from degenerating polymorphs as already stated. These cells become larger and their nuclei are oval, long oval or rod shaped and the protoplasm contacts the egg white by projections and phagocytizes it. Macrophages hypertrophy with phagocytosis. Piknosis of nuclei and vacuoles in the protoplasm are found as regressive changes, but they are relatively few.

Although polymorphs exhibit some phagocytic activity early, phagocytosis by macrophages is much more conspicuous. They not only surround egg white, but invade the crevices deeply and extend protoplasm into the egg white. Some of them are seen to be buried in the substance by their phagocytosis of surrounding substance and others get together making irregular hollows around the edge of the egg white. Some small particles of the egg white in its outer part are phagocytized almost completely and only

a collection of cells or a small particle of substance is seen in the center. Such findings suggest that the resorption of small caseous foci without any traces may occur by the same mechanism.

The formation of giant cells of foreign body type is found only in the case of egg white. On the 3rd and 4th days, some or many cells get together compactly and their protoplasm is believed to coalesce. They are probably macrophages in the early stage of forming giant cells. In addition, collections of lymphocytes are also found but it is not clear whether they form giant cells or not.

On the last, 7th, day, a complete giant cell of foreign body type exists in the surrounding connective tissue layer; protoplasm is eosinophilic and about 40 nuclei are arranged, not radially but rather in the same direction. It is different from a Langhans giant cell. The reason why it does not appear in the case of other proteins is not clear.

Other proteins also cause the migration of macrophages following that of polymorphs. Albumin causes reactions similar to egg white. Albumin coagulated by heat is more digestible than powdered albumin. The similarity of digestibility of egg white and albumin is natural since 90% of egg white is albumin.

Globulin collects the most phagocytic cells but is most hard to digest. Casein is easily digested and only traces of it are found in some specimens on the 7th day. Gelatin, being different from other protein, dissolves early in the subcutis because of its easy solubility in water. In some specimens no gelatin is found around the polymorphs which have migrated into the liquid gelatin and phagocytized it. Most of the dissolved gelatin is digested by polymorphs. But some solid particles of gelatin are found phagocytized by macrophages on the 7th day. This shows that liquid protein is absorbed easily, and solid protein can undergo cellular phagocytosis, too. Liquid protein such as dissolved gelatin is easily absorbed by polymorphs early and by macrophages later. Some solid proteins are phagocytized by polymorphs but most of them are phagocytized by macrophages, depending chiefly on the degree of digestibility.

Some lymphocytes and plasma cells are found later but there is no evidence that they take much part in the phagocytosis of proteins.

Proliferations and migration of fibroblasts are found starting 1-2 days after insertion and parallel the collecting of macrophages. The production of collagenous fibers occurs 3-4 days later. This is earlier than in Stern's⁽⁷⁾ experiment. He reported that fibroblasts invaded the table area at an average of 6 days after the insertion of the chamber and the first delicate fibrils appeared 4-5 days later in his investigation of transparent chamber in the rabbit's ear.

Early fibroblasts are oval or bipolar in shape and then gradually increase in number and are closely packed together. Later, large asteroid fibroblasts are found in the outer areas. New collagenous fibers are fine and stained with difficulty with Van Gieson's connective tissue stain, being differentiated from previously existing fibers. They surround the substance, forming one layer and they are seen also in the crevices.

In the case of egg white, the reactions scarcely spread beyond the connective tissue layer. Collagenous fibers are conspicuous in the outer areas and they are arranged centripetally in inner layer with the exception of the case of globulin. Does this indicate that globulin will be dealt with by isolation and the others by organization?

Finally, the staining of proteinase activity was done by Takamatsu's^(8, 9, 10) method. The histochemistry of proteinase activity has remained undeveloped. This method is different from other histochemical methods of ferments in principle. Although this method contains some further problems to be solved in its principle and technique, it was added to the experiment as one clue. The results are as follows: No specific difference was observed between the kinds of proteins inserted. The granulation tissue is markedly positive and polymorphonuclear leukocytes show the activity on an alkaline medium (pH 8.6) but do not in acid media (pH 6.5 and 2.7). Macrophages show the activity in both media. Anderson⁽¹¹⁾ stated that the proteolytic enzyme of polymorphs is active chiefly in an alkaline medium in man. Branes⁽¹²⁾ reported his biochemical estimation that polymorphs in rabbits are active in acid media, and in cat active in both media, especially in alkaline media. These differences in data can not be criticized by us since our experiments were performed in rats.

Summary

1) Egg white, egg albumin, globulin, casein and gelatin were inserted into the subcutis of albino rats for the study of histological reactions to foreign solid proteins. The reactions were investigated from 2 hours to 7 days after insertion of each protein by fixed and stained specimens.

2) No fundamental differences were found in the reactions to each protein, although differences in the degree of intensity existed.

3) Both liquid and solid proteins were phagocytized by migrated cells with some differences of digestibility. Gelatin was most easily digested, globulin was difficult to digest and the other three kinds of protein were moderately digestible.

4) The reactions were mildest in the case of egg white and strongest in the case of globulin. Vascular dilatation, migration and phagocytosis of polymorphonuclear leukocytes and macrophages, migration and proliferation of fibroblasts and production of collagenous fibers were observed. Migration of lymphocytes and plasma cells was almost negligible.

5) Swelling of endothelial cells was found in the case of globulin and egg white, especially in the former.

6) Giant cells of the foreign body type were found only in the case of egg white.

7) The activity of proteinase was strongly positive in granulation tissue. In polymorphs, it was positive in alkaline medium, and in macrophages, in both media.

References

- 1) CLARK, E. R. and E. L. CLARK: *Am. J. Anat.* **57**: 385-435, 1935.
- 2) SPECTOR, W. G.: *J. Path. & Bact.* **113**: 93-110, 1951.
- 3) CLARK, E. R. et al.: *Am. J. Anat.* **59**: 123-173, 1936.
- 4) CLARK, E. R. and E. L. CLARK: *Anat. Rec.* **27**: 137-158, 1922.
- 5) CLARK, E. R. and E. L. CLARK: *Am. J. Anat.* **46**: 149-185, 1930.
- 6) ANDERSON, W. A. D.: *Pathology 1953* The C. V. Mosby Co. p. 23.
- 7) STERNS, M. L.: *Am. J. Anat.* **66**: 133-176, 1940.
- 8) TAKAMATSU, H. and K. Wada: *Trans. Soc. Path. Jap.* 43 Ed. Gener. 1954.
- 9) TAKAMATSU, H., et al.: *Trans. Soc. Path. Jap.* 43 Ed. Region. 1954.
- 10) TAKAMATSU, H., et al.: *Trans. Soc. Path. Jap.* 44 Ed. Gener. 1955.
- 11) ANDERSON, W. A. D.: *Pathology 1953* The C. V. Mosby Co. p. 38.
- 12) BRANES, J. M.: *Brit. J. Exp. Path.* **21**: 264-275, 1940.

Explanation of the plates

Fig. 1 Case of egg white; 7th day. Many macrophages migrate around the egg white and invade the crevices. The egg white undergoing phagocytosis forms irregular hollows with many cells along the edge, and some particles are isolated and surrounded by many cells. A giant cell of foreign body type is seen in the surrounding tissue at the upper site of the plate. ($\times 100$)

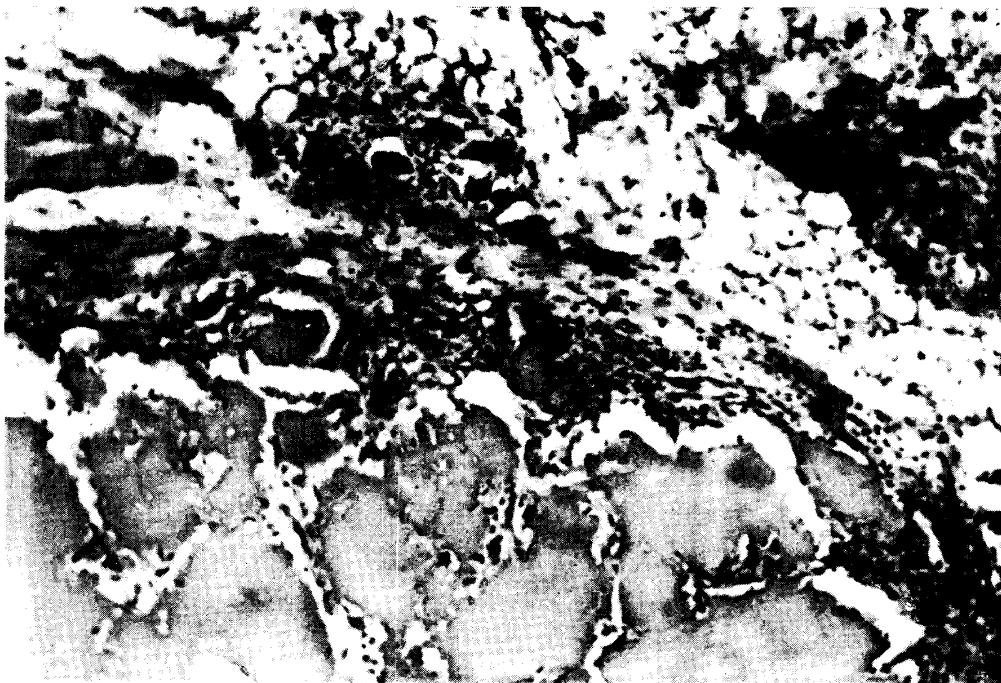


Fig. 2 Case of egg white; 5th day. A migrated macrophage shows mitosis near by the egg white. The right dark field shows the congregation of cells at the edge of the egg white. ($\times 900$)

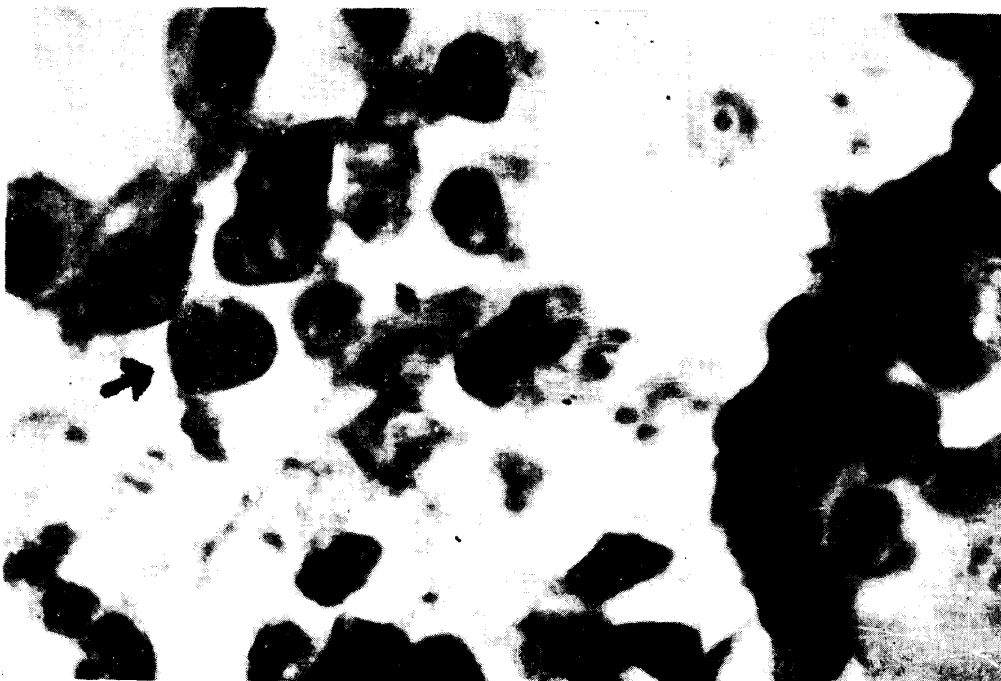

Fig. 3 Case of albumin; 3rd day of experiment II. The particles of albumin scattered and induced migration of wandering cells. The cells are composed of polymorphs and macrophages, and show phagocytic action. Vascular dilatation and stagnation of blood are seen at the lower part of the plate. ($\times 100$)

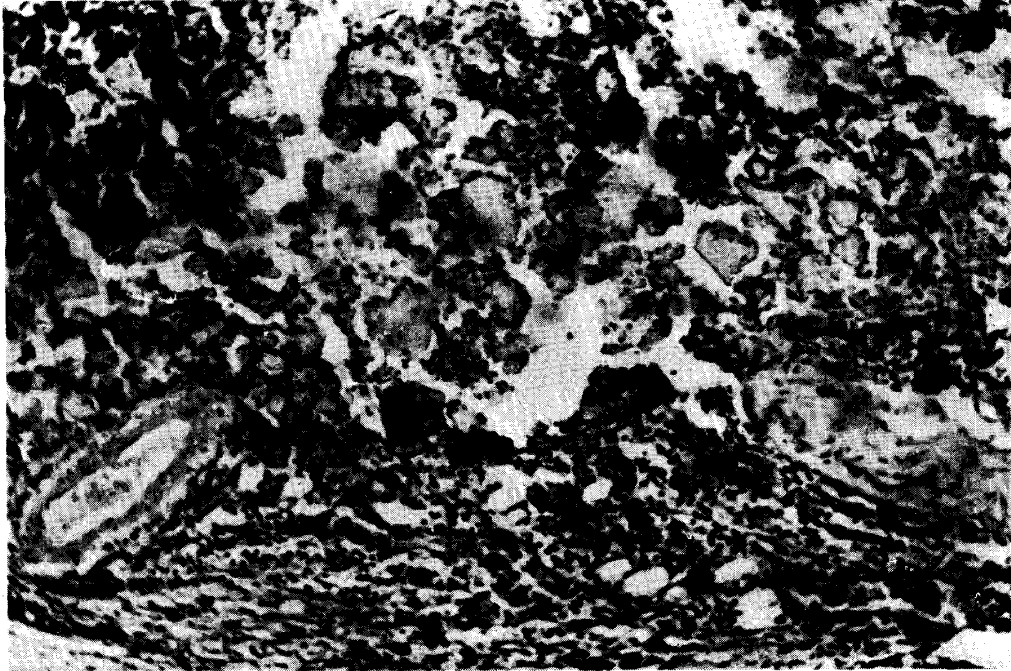


Fig. 4 High power view of the particles of albumin undergoing phagocytosis shown in Fig. 3. ($\times 400$)

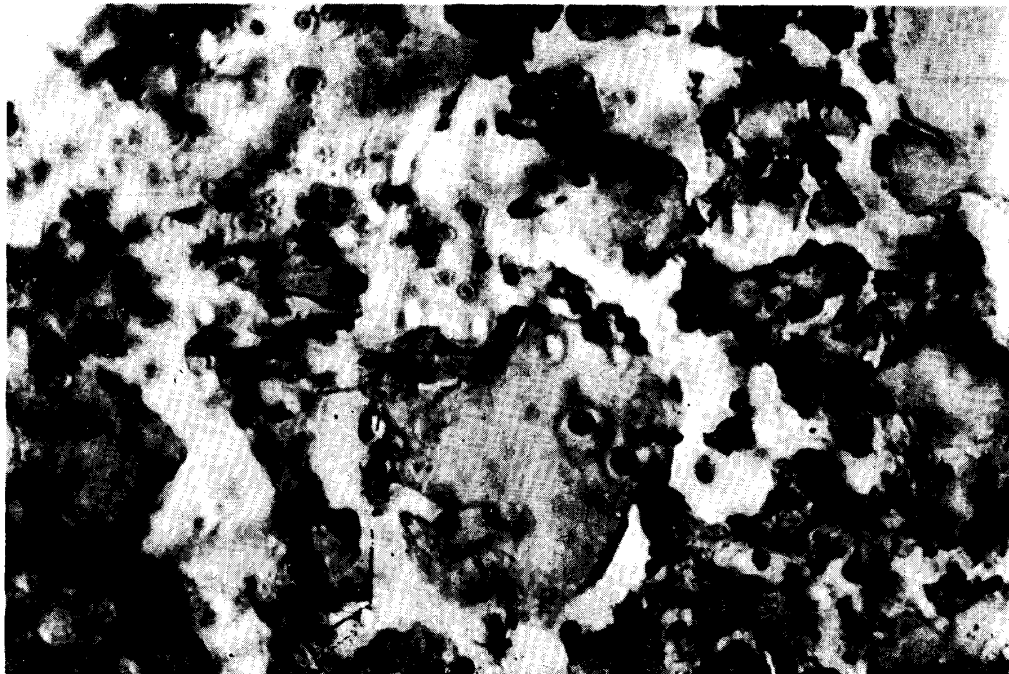


Fig. 5 Case of globulin; 7th day of experiment I. The particles of globulin is difficult to digest. Many wandering cells surrounded the particles, but they have tendency to degenerate. ($\times 100$)

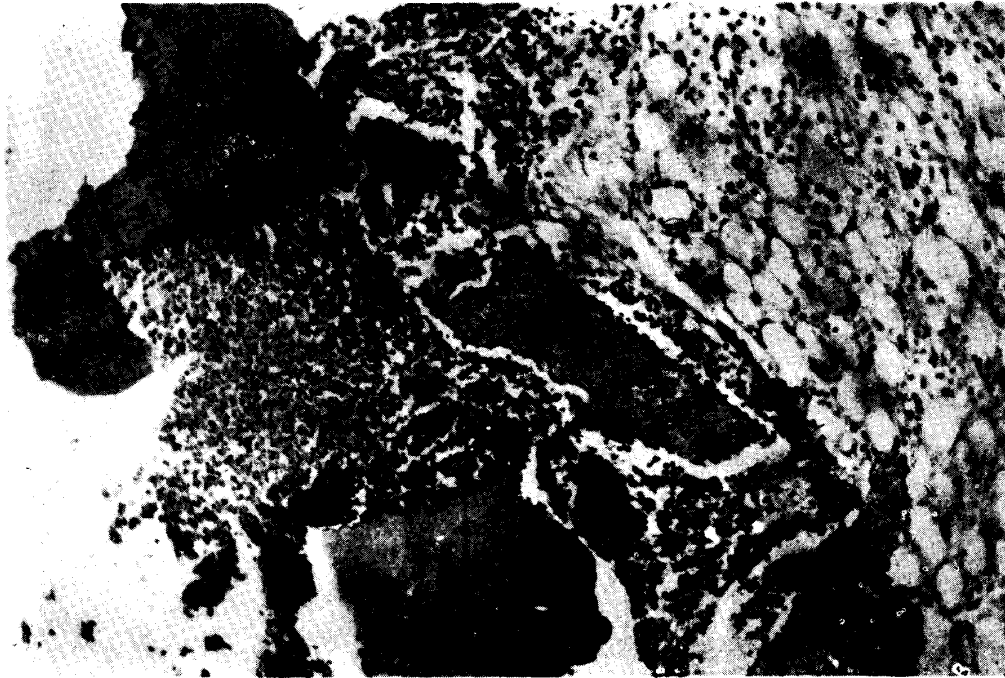


Fig. 6 Case of globulin; 2nd day of experiment I. Swelling of the endothelial cells of the blood vessel is seen in the muscle layer far from the globulin. The nuclei project into the vascular lumen. ($\times 400$)

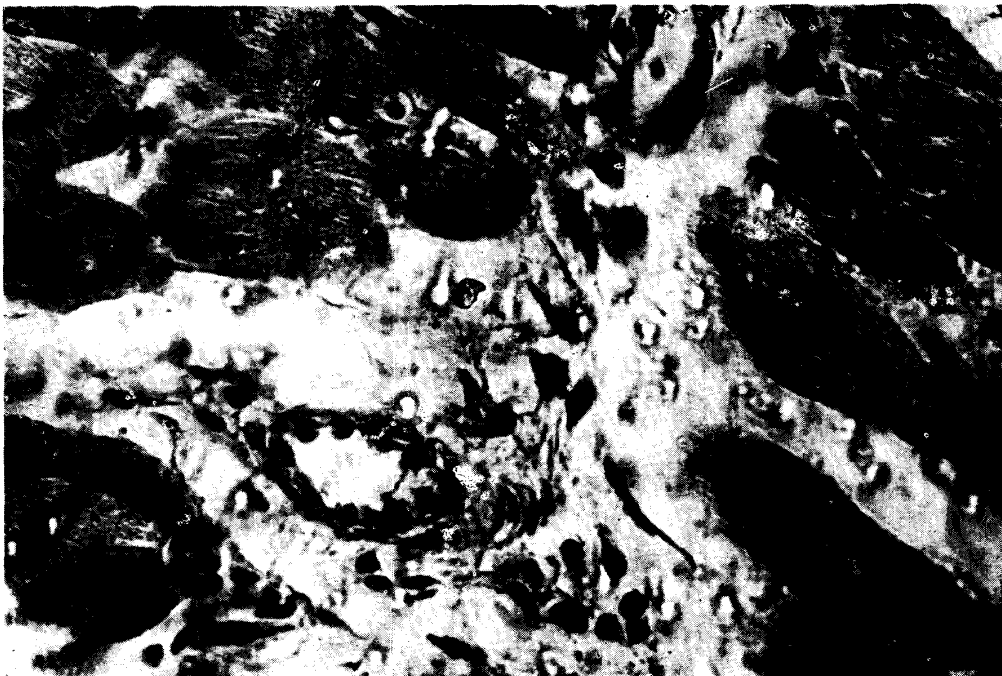

Fig. 7 Case of casein; 7th day of experiment I. The casein is almost completely digested, and the surrounding of it is the fibrin layer. These layers contain mostly degenerating cells. The granulation tissue has proliferated in the outermost layer. The inside two layers are clearly separated from the granulation tissue. ($\times 100$)

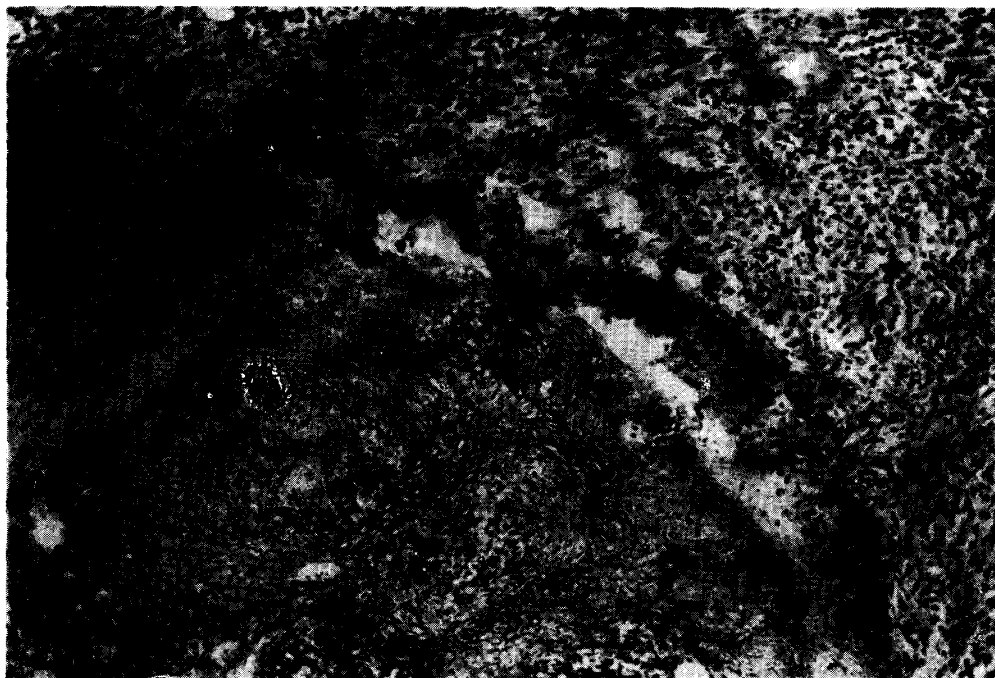

Fig. 8 Case of gelatin; 24th hours. The gelatin has already dissolved, and many polymorphs migrated into it. No gelatin is found around the polymorphs which have migrated into the liquid material and phagocytized it. ($\times 100$)

