

# A New Histochemical Demonstration of Dehydrogenase Activities

(Gold-Tellurite Method)

By

**Hideo TAKAMATSU\*** and **Kimiaki OBAYASHI**

高松 英雄

大林 公明

(Received Nov. 28, 1954)

## Introduction

Dehydrogenase catalyses the processes of dehydrogenic oxidations. In these processes hydrogen is transferred from one substances, namely the substrates, to other substances, namely hydrogen acceptors. Therefore, hydrogen acceptors, are reduced in the oxidation of the substrates. Hydrogen acceptors which are converted to coloured substances by reduction from the colourless state, may be used as indicator of dehydrogenic oxidation. Moreover, if the converted acceptor is insoluble in nature and is precipitated in water from an originally soluble substance, it can be used as a histochemical indicator.

As indicators of the histochemical method of demonstrating dehydrogenase, there are now two kinds of compounds. The first is a group of tetrazolium compounds. The other is tellurite. The usefulness of various tetrazolium compounds is already known and there are some reviews about these compounds and many publications concerning experiments with these compounds. The experiments with tellurite seem to be very rare. Both methods have excellent points, but each one also has certain defects.

The tetrazolium compounds are sensitive indicators, as is well known, and are brightly coloured, but the formazans, the reduced compounds of tetrazoliums, are soluble in organic solvents and occasionally stained fat droplets of the tissues. Moreover, the formazan dyes have a tendency to secondary organization into

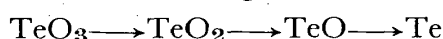
\* From the Division of Pathology (Chief; H. Takamatsu) of the Tuberculosis Research Institute, Kyoto University.

coarse crystalline precipitates. Because of fat and lipid solubility, it is difficult to dehydrate and to mount them in balsam. The tellurite method is also sensitive enough, but the elementary tellurium, the reduced product of the tellurite has a black colour under the microscope. So the appearance of a site of weak reaction may be mistaken occasionally for shadows of photo-refraction.

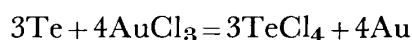
The defects of the tetrazolium methods are hard to improve, so the present authors devised a new method using tellurite. The outline of this method has already been reported in other papers. In this report we describe our new method in its practical applications using the substrates of dehydrogenase activities.

### The principle of the new method

As indicator we used potassium tellurite. The formula of this compound may be written  $K_2TeO_3$ . Tellurite will change to elementary tellurium by reduction:



This elementary tellurium will adhere to the sites of dehydrogenase activity in the sections. In a gold chloride water solution, this tellurium reacts with gold chloride in the following way and metallic gold will appear at the site of elementary tellurium.



Metallic gold is visible as a blue and violet colour under the microscope, and as is well known, it is insoluble in water and in many organic solvents. Thus, the new method seems to be an ideal one.

### Practice of the method

Requirements; (1) Substrate solution:— As the substrate of dehydrogenase reaction, we used succinic acid, lactic acid, l-maleate, glucose, l-glutamic acid, glycerophosphoric acid, and ethyl alcohol. The concentration of all these solutions are 0.2 Mol. The reaction of these solutions must be corrected to neutral. (2) Potassium tellurite solution;— In phosphate buffer solution (1/15 Mol) of pH 7.4 potassium tellurite is dissolved in the proportion of 0.2 per cent. (3) Substrate mixture;— Equal parts of substrate solution (1) and potassium tellurite solution (2) were mixed before using. Beside this substrate mixture, gold chloride water solution (0.05 per cent), Sod. thiosulfate solution (1 to 5 per cent) and other chemicals such as formalin solution, gum syrup and gelatinum must be ready.

Procedure; Freshly removed tissues were cut about 1 mm thick by hand, using a razor blade, and these thin tissue pieces were incubated immediately in the substrate mixture at 37°C for about 10 hours. If some glass wool is spread in the incubating vessels, the reaction takes place more favourably. After the incubation, the tissue pieces were fixed in the formalin solution. Before sectioning, the sections were washed with water and embedded in gelatin and made into frozen

sections in the usual way. These tissue sections were immersed in the gold chloride solution for 20 minutes to 2 hours; then washed in water over night; then immersed in the Sod. thiosulfate solution 10 to 30 minutes; then rewashed in water and mounted in gum syrup. For counter staining, lithion carmine, safranin and nuclear fast red were found to be suitable.

#### **Results obtained by this new method**

The tissue piece were stained in the incubations solution in a little while. However, care must be taken to prolong incubation sufficiently, since the reagent penetrates rather slowly into the midparts of the pieces. The colour of the pieces will be converted to black by the dehydrogenic oxidation and this colour is stable in the formalin solution. The sections of these pieces were also stained black in various grades according their enzymatic activities. This staining is due to deposits of elementary tellurium and converts to blue violet upon immersing in the gold chloride solution. This new colour is a sign of the formation of metallic gold. As already stated, metallic gold is stable for many organic solvents. Sufficient washing after immersing in gold chloride solution and in sod. thiosulfate solution makes the colour intense. Immersing the sections in gold chloride solution too long occasionally caused nonspecific stainings of fibrils and nuclei. Therefore, a moderate immersing (about 25 minutes) must be used.

The distribution of dehydrogenase activities using this new method are identical with that of the tetrazolium method. The experiments on the tissue dehydrogenase activities will be reported by the present authors in other papers. The results of the experiments with many substrates will also be stated in another report. In this paper we showed only some plates of the experiments without using any substrates.

#### **Comment**

The principle of our new method is based upon the replacing of elementary tellurium by metatallic gold. The first step of this method is the reduction of tellurite and the fomation of elementary tellurium. This step is already recognized by many authors and the sensitivity of this reaction is also accepted. The end product is changed by the present authors. Metallic gold is ideal as the endproduct of histochemical method. With slightly care, the experiment can be performed without any defects. Moreover, the endproducts of this method result in bright colours and are stable to many reagents. This new method removes many of the defects of other tertrazolium compound methods and of the simple tellurite method.

#### **Summary**

We described a new histochemical method of demonstration of dehydrogenase activities. In this method potassium tellurite is used as a hydrogen acceptor and

the deposition of elementary tellurium is replaced by metallic gold. Thus, this new method results in a bright colour and is stable to many reagents. Moreover this new method is very easy to carry out.

#### Acknowledgement

This research was done under a grant from the Ministry of Education of Japan. We also received much supporting from Dr. Tadasu Ito, Chief director of the Research Institute for Thyroid Diseases in Tokyo. We here express our gratitude for this aid.

#### References

- 1) KUHN, R. und D. JERCHEL; *Berichte d. deut. chem. Gesellsch.*, **74** 949. 1941.
- 2) KLETT, A.; *Ztschr. f. Hyg.*, **33** 137, 1900.
- 3) WACHSTEIN, M.; *Proc. Soc. Exp. Biol. and Med.* **72** 175. 1949.
- 4) TAKAMATSU, H and K. OBAYASHI; *Trans. Soc. Path. Jap. Liber* **43** Editio Reg. 1953.
- 5) SHELTON, E. and W.C. SCHNEIDER; *Anat. Rec.*, **112** 61. 1952
- 6) SELIGMAN, A.M., and RUTENBERG, A.M.; *Science*, **113** 317, 1951.
- 7) SMITH, F.E. *Science*, **113** 751, 1951.

### Expranation of the plates

Fig. (1) Dehydrogenase activities in the thyroid gland of a case of Basedw's disease. Intensed reactions are dcmonstrated, especially in the proliferatings epithelium.

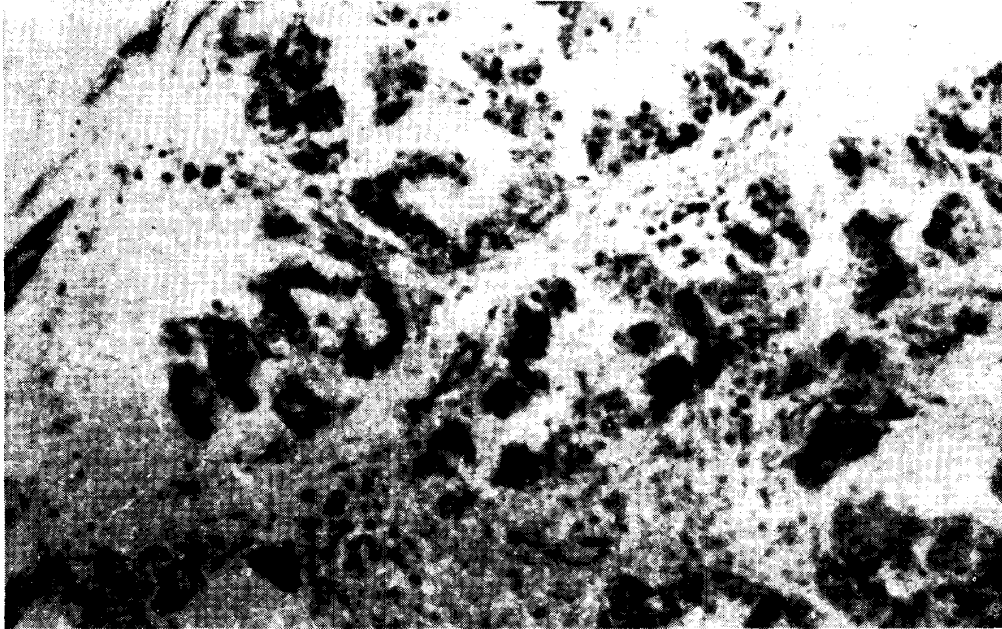

Fig. (2) Same reaction in the epithelium of the gastric glands of a normal rat.

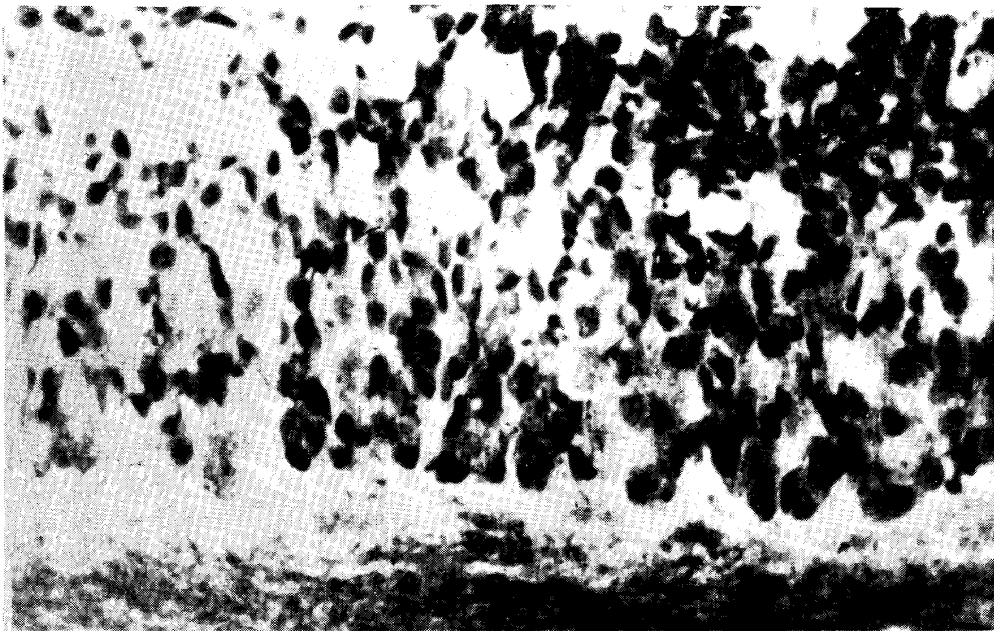

Fig. (3) Dehydrogenase reactio in the mucous epithelium of the small intestine of a normal rat. Intense reactions are observed in the intestinal gland.




Fig. (4) Dehydrogenase reaction in the liver of anormal rat. The construction of the tissue is destroyed to some extent by sectioning. The reaction products are seen as granules and are dense in some parts and coarse in other parts in the protoplasma, but can scarcely be seen in the nuclei.

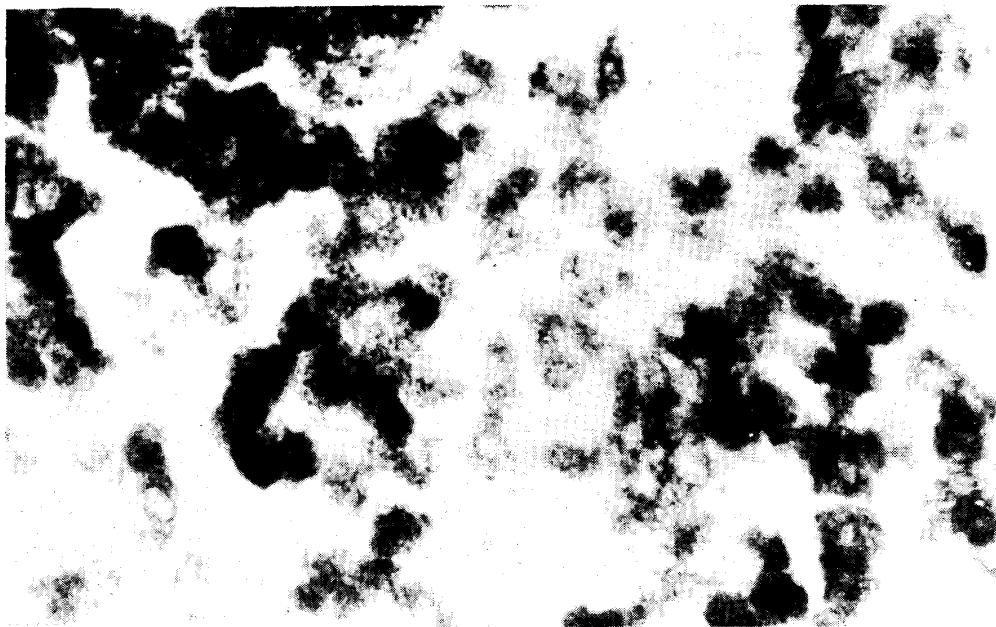


Fig. (5) Adrenal cortex of a normal rat. Same reaction. Marked reactions are seen in the cortical cells, especially in the zona fasciculata. Small amounts of reaction products are seen in the zona reticularis but almost none in the zona glomerulosa.




Fig. (6) Submucous layer of the uterus of a normal rat. Dehydrogenase reaction. Reaction products are seen in fibrocytes and other cells.



Fig. (7) Dehydrogenase activities in a normal rat's kidney, demonstrated by the new method.

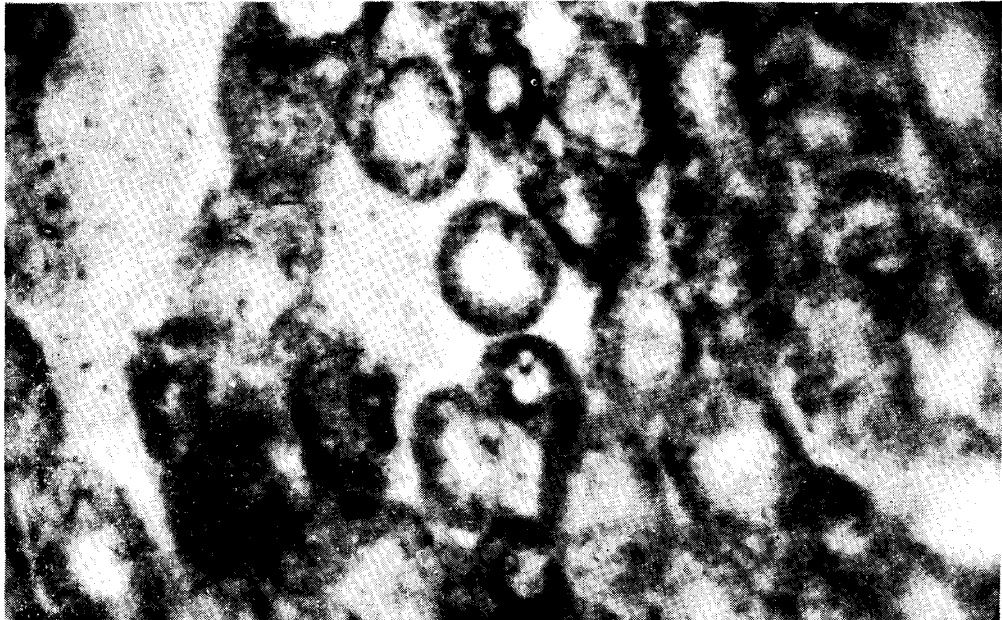


Fig. (8) Kidney of a normal rat. Dehydrogenase activities are demonstrated using ditetrazolium. Formazan is markedly crystallized.

All of these slides were prepared without adding any substrates.

