

## Dynamic Observation of Passavant's Ridge in Cleft Palates

Michio KAWANO, Fumiko TANOKUCHI, Yoichi OKA,  
Tatsuzo TAIRA, Hisayoshi KOZIMA and Iwao HONJO

There has been some controversy regarding the significance of Passavant's ridge which is formed at the retropharynx in cleft palate patients. It has not been determined whether the ridge has any role in compensation for velopharyngeal inadequacy for cleft palate speech or not. Through fluorovideoscopy and fiberscopy which permitted direct visualization of dynamic condition of the velopharynx, significance of Passavant's ridge in velopharyngeal function was re-examined in this study.

### SUBJECTS

A hundred and forty cases with cleft palate, including submucous cleft and congenital velopharyngeal incompetence, were examined. The subjects who had

Table 1 Cleft types, velopharyngeal function and ages of the subjects

[Cleft type]	CL/P	CP	SMCP	CVPI			
total subject (n=140)	65	26	22	27			
group with the most prominent ridge (n=12)	8(12.3%)	3(11.5%)	1(4.5%)	0			
[V-P function]	competence	slight inompetence	incompetence				
total subject (n=140)	15	70	55				
group with the most prominent ridge (n=12)	3(20%)	6(8.6%)	3(5.5%)				
[age]	-5	6-10	11-15	16-20	21-25	26-30	31-
total subject	28	67	13	10	8	10	4
group with the most prominent ridge		2(3.0%)	1(7.7%)	4(40%)	3(37.5%)	2(20%)	

CL/P: cleft lip and palate  
 CP: cleft palate  
 SMCP: submucous cleft palate  
 CVPI: congenital velopharyngeal incompetence

Michio KAWANO (川野通夫): Dept. of Otorhinolaryngol., Faculty of Medicine, Kyoto Univ.  
 Fumiko TANOKUCHI (田野口二三子): Dept. of Otorhinolaryngol., Kagawa Medical School.  
 Yoichi OKA (岡 洋一): Wakayama Prefecture, the Home for the Widows and their Children.  
 Tatsuzo TAIRA (平良達三): Dept. of P.R.S., Faculty of Medicine, Kyoto Univ.  
 Hisayoshi KOZIMA (児嶋久剛): Dept. of Otorhinolaryngol., Kurashiki Central Hosp.  
 Iwao HONJO (本庄 巖): Dept. of Otorinolaryngol., Faculty of Medicine, Kyoto Univ.

undergone pharyngeal flap operation were excluded from the observation. Type of cleft, velopharyngeal competence and their ages are presented in Table 1.

#### METHODS

Fluorovideoscopy of lateral and frontal view of the velopharynx were utilized for the assessment of velopharyngeal function during phonation. The patients were laid supinely on the bed. Barium sulfate of about 10 cc was instilled into the oral cavity and through the nostril. U-arm type X-ray apparatus (PHILIPS OPTMUS M200) was used. Simultaneous recording of the fluorovideoscopic image and speech sound was made with a videocassette recorder (NATIONAL NV-9200).

The fiberscopy (OLYMPAS ENF TYPE P) of the velopharynx through the nose was performed in some cases. It was recorded with a videocassette recorder (SONY VO-2960) and a videocamera (SONY DEX 1850).

For analysis of the dynamic process of velopharyngeal closure, the video tape was stopped every 0.1 seconds to trace on the transparent sheets by the use of an editing controller (SONY RM-430).

#### RESULT

##### 1) Incidence of formation of Passavant's ridge

Among 140 cases examined, 42 cases (30%) showed various degree of Passavant's ridge (Fig. 1). Twelve cases (8.5%) exhibited prominent protrusion of the retropharynx during speech. ("The group with the prominent ridge" hereafter) (Fig. 2, 3).

The patients in this group ranged from 5 to 30 years of age and the largest number was over 16 years old. Eight cases had cleft lip and palate, 3 cases had

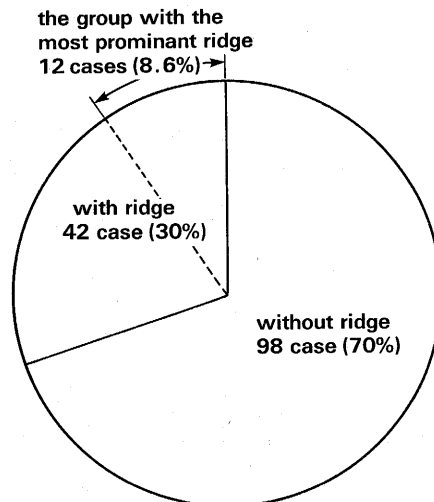
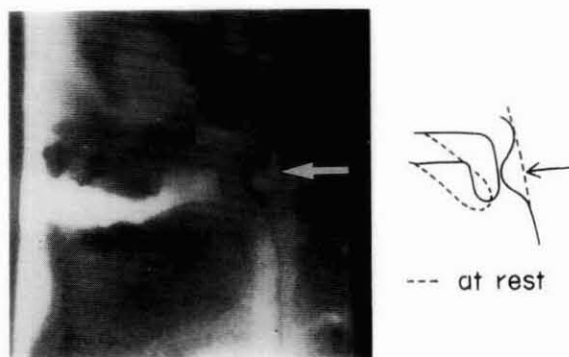
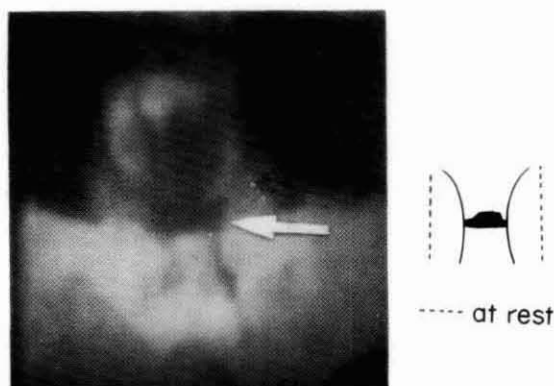


Fig. 1 The incidence of formation of Passavant's ridge



An arrow indicated Passavant's ridge

Fig. 2 Lateral fluorovideoscopic view of the velopharynx during [a] production



An arrow indicated Passavant's ridge

Fig. 3 Frontal fluorovideoscopic view of the velopharynx during [a] production

cleft palate only and 1 case with submucous cleft. There was no patients with congenital velopharyngeal incompetence in this group. Velopharyngeal function evaluated by fluorovideoscopy was competent in 3 cases, slightly incompetent in 6 cases and incompetent in 3 cases.

## 2) Analysis of movement of Passavant's ridge

Through the lateral fluorovideoscopy of the velopharynx, the position of the ridge was examined in the group with the prominent ridge (Fig. 4). All of 12 cases demonstrated their ridge at the level of the atlas slightly lower than the upper margin of the elevated velum during speech.

Through the frontal fluorovideoscopy of the pharynx, the movement of lateral pharyngeal walls were classified into three groups; good mobility, moderate mobility and poor mobility (Table 2). It was noted that 75% of patients with prominent ridge had good mobility, 25% had moderate mobility of the pharyngeal walls. Contrarily, the patients without Passavant's ridge showed only 23% of good mobility, 41% of moderate and 36% of poor mobility of the pharyngeal walls. Thus it was

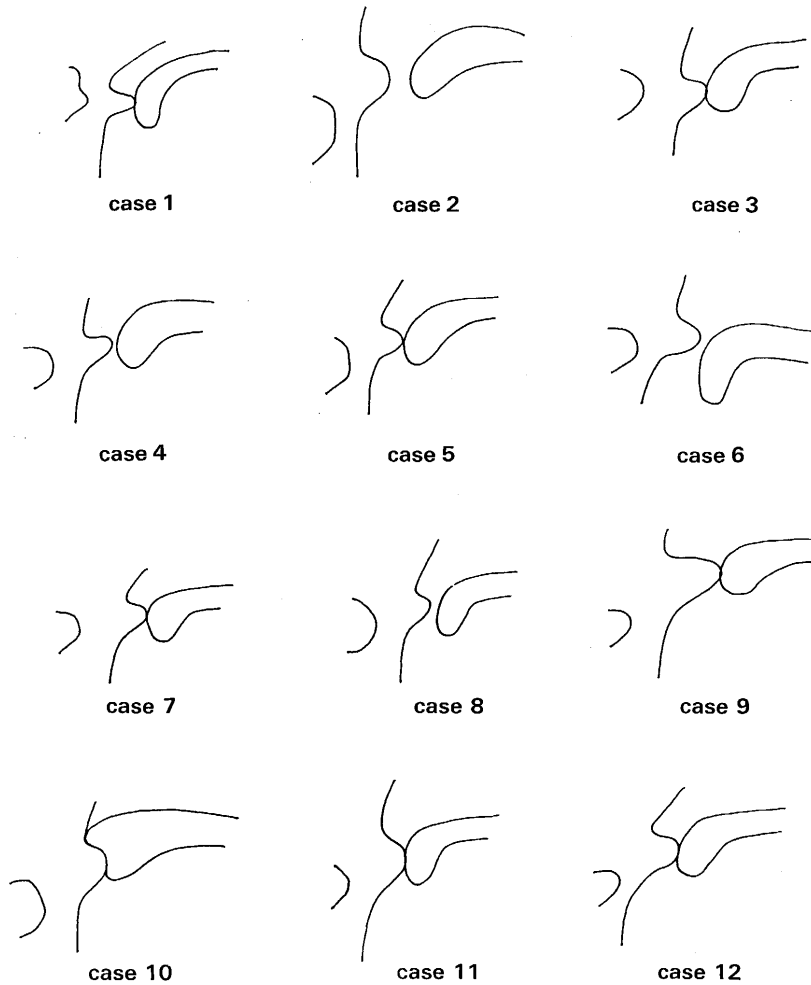


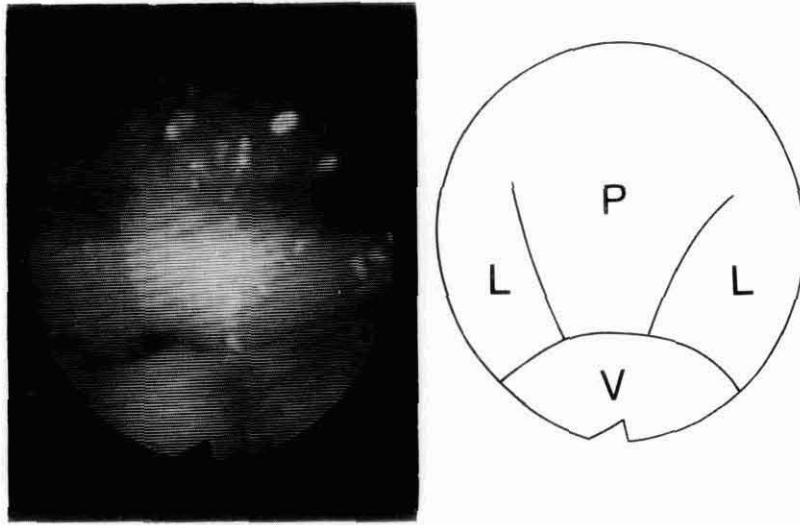
Fig. 4 Position of Passavant's ridge in relation to the atlas and the soft palate

demonstrated that the patients with prominent ridge had sufficient movement of lateral pharyngeal walls during speech.

Eleven cases with the prominent ridge were examined by endoscopy to evaluate the process of velopharyngeal closure (Fig. 5). It was revealed that velopharyngeal closure was accomplished by simultaneous movements of the soft palate, lateral pharyngeal walls and Passavant's ridge. Among them, 7 cases demonstrated sphincter like movement of the velopharynx and 4 cases exhibited the velar move-

Table 2 Mobility of lateral pharyngeal walls

[lateral walls mobility]	good	moderate	poor
group with the most (N=12) prominent ridge	9(75%)	3(25%)	0
group without ridge (N=98)	23(23%)	40(41%)	35(36%)



P: Passavant's ridge L: lateral pharyngeal wall V: velum

Fig. 5 Fiberscopic view of the velopharynx at during [pu] production  
Velopharyngeal port closed by the sphincteric movements of the velum, lateral pharyngeal walls and Passavant's ridge

ment superior to the level of the lateral and posterior wall (Passavant's ridge) movements.

Temporal analysis of the movement of Passavant's ridge in relation to that of the soft palate and lateral pharyngeal walls was made during [fi] production (Fig. 6, 7). It was revealed that the ridge and the soft palate moved from the static position to the maximum protruded and elevated position in 0.3 seconds, while they returned to the original position in 0.2 seconds. On the other hand, lateral

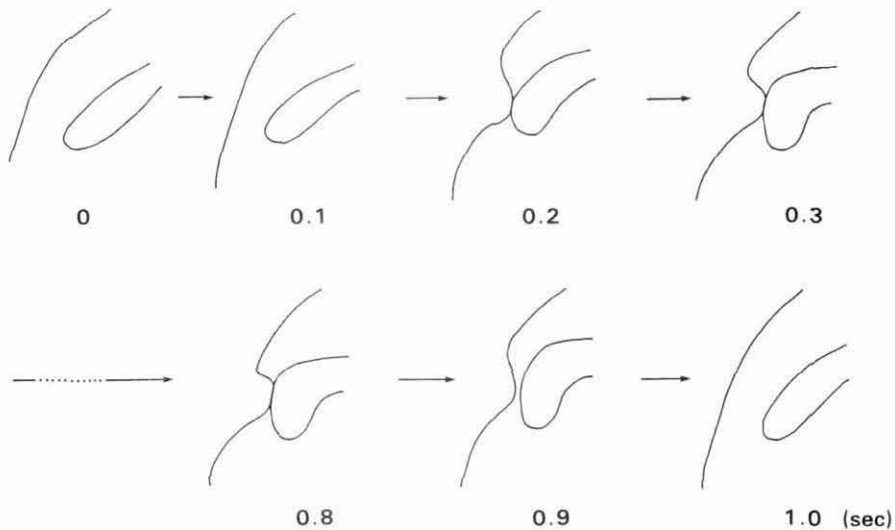


Fig. 6 Process of formation of Passavant's ridge in relation to the velum

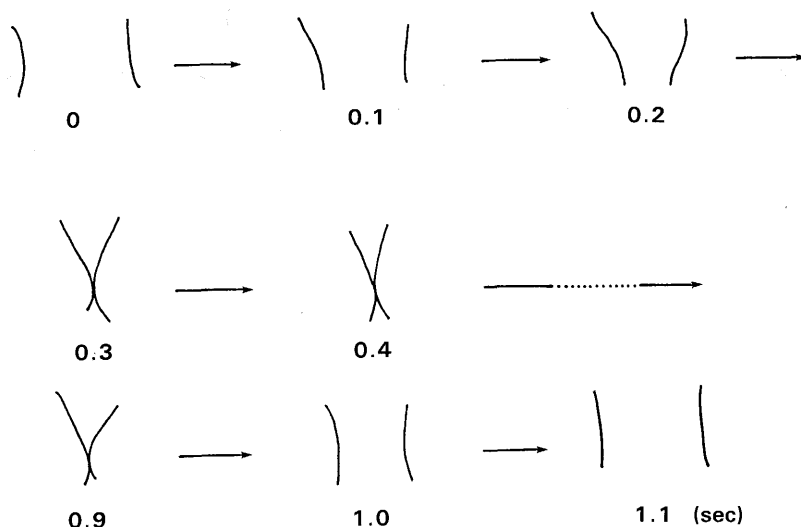


Fig. 7 Process of the medial movement of the lateral pharyngeal walls during [fi] production

pharyngeal walls moved from the static position to the medial one in 0.3 or 0.4 seconds and returned to the initial position in 0.2 seconds. Namely, it took almost the same duration for Passavant's ridge, the soft palate and lateral walls to move from the static position to the dynamic position.

### 3) Relationship between Passavant's ridge and articulation

Passavant's ridge during phonation of Japanese vowels and C-V syllables such as [pa], [ta], [ka], [fi] which required adequate velopharyngeal closure, and nasal sounds such as [mi], [na] which required no velopharyngeal closure was examined by nasoendoscopy (Table 3).

For nasal sounds, the degree of formation of the ridge was small as compared with plosives and fricatives. On producing Japanese vowels, plosive and fricative consonants, 7 cases showed formation of the ridge for all sounds tested. One case showed formation of the ridge only for consonants but not for vowels. Three cases showed inconsistent formation of the ridge for vowels, and remaining 3 cases showed inconsistent formation of the ridge for vowels and consonants. Each of the 3 cases demonstrated faulty articulations for plosives and fricatives. However, after they obtained normal articulation by speech therapy, Passavant's ridge was formed for all vowels plosives and fricatives.

In the following, representative 3 cases are presented.

(Case 1) A 4 year-old boy with submucous cleft palate.

He demonstrated faulty articulation such as omission for all consonants at initial examination. On producing [a] and [pɯ], Passavant's ridge was formed and velopharyngeal port was almost closed. But, for the other vowels and consonants, no ridge was formed and velopharyngeal closure was inadequate. His articulation improved as he became older. When Japanese consonants (C-V

Table 3 Mobility of Passavant's ridge on phonemes

case	a	i	u	e	o	p	t	k	s	f
1	+	-	+	+	+	+	-	-	-	-
2	+	-	-	-	±	±	±	±	-	-
3	+	-	-	-	-	+	+	+	+	+
4	-	-	-	-	-	+	+	+	+	+
5	+	+	+	+	+	+	+	+	+	+
6	+	+	+	+	+	+	+	+	+	+
7	+	+	+	+	+	+	+	+	+	+
8	+	+	+	+	+	+	+	+	+	+
9	+	+	+	+	+	+	+	+	+	+
10	+	+	+	+	+	+	+	+	+	+
12	+	+	+	+	+	+	+	+	+	+

+ formation of the ridge

- non-ridge

± inconsistent formation of the ridge

case 1, 2, 3... (+) for all vowels and consonants after  
articulatory correction

syllables) such as [pa] [ta] [ka] became normal, Passavant's ridge was formed during phonation of these consonants and velopharyngeal closure became adequate. (Case 2) A 20 year-old male with cleft lip & palate.

He demonstrated faulty articulation of pharyngeal plosives for [k] sound and laryngeal fricatives for [s] and [ʃ] sounds. Passavant's ridge was noted with slight incompetent velopharyngeal closure for vowels and [p] [t] [k] sounds. However, for [s] [ʃ] production, velopharyngeal closure was inadequate, and neither elevation of the soft palate nor formation of the ridge was noted. When articulation became normal after 2 months of speech therapy, Passavant's ridge was formed for [s] [ʃ] sound and adequate velopharyngeal closure was obtained.

(Case 3) A 18 year-old male with cleft palate.

At his initial examination, plosives and fricatives were weak and [k] sound was omitted occasionally. Passavant's ridge was noted only during production of vowel [a], while it was slight for production of [p] [t] [k] sounds. After 4 months of speech therapy, articulation improved markedly and the velopharyngeal closure improved. With the improvement of velar and lateral wall movement, the prominence of Passavant's ridge increased. The ridge emerged prominently for vowels except [a] and also plosives and fricatives. Velopharyngeal closure improved to nearly normal.

Thus the subjects with faulty articulation obtained Passavant's ridge which improved velopharyngeal closure by intensive speech therapy, simultaneously with the improvement of lateral wall movement and velar mobility.

#### DISCUSSION

As to the incidence of Passavant's ridge, Skolnic<sup>1)</sup> reported that 10 out of

30 patients with cleft palate exhibited the ridge. In the present study we found the Passavant's ridge in 42 (30%) out of 140 subjects. This incidence is in good coincidence with that of previous report.

Present study was focused on the group with prominent ridges. The ridge was found in 12.3% of cleft lip and palate case, in 11.5% of cleft palate only and in 4.5% of submucous cleft, while none of congenital velopharyngeal incompetence. Thus the ridge is supposed to appear in cleft palate and rarely in congenital velopharyngeal incompetence.

As for the relationship between the ridge and velopharyngeal competence, the ridge was noted in 20% of cases with competent velopharyngeal closure, in 8.6% of cases with slight velopharyngeal incompetence and in 5.5% of cases with velopharyngeal incompetence. It appears that the incidence of ridge formation is high in the subjects with velopharyngeal competence, but it may partly be due to the improvement of velopharyngeal function by the Passavant's ridge itself.

Regarding the ages of the subjects with Passavant's ridge, the incidence of ridge was also high in patients over 16 years old in our study. It was supposed that the ridge became prominent in compensating the velopharyngeal closure as the subjects became older.

As to the position of Passavant's ridge, all 12 cases with the prominent Passavant's ridge showed the ridge in front of the atlas slightly lower than that of the upper edge of the elevated velum during speech. Seven of 11 cases examined by the endoscopy showed velopharyngeal closure of sphincter like movements<sup>2)</sup> by the soft palate, lateral pharyngeal walls and Passavant's ridge at the level of the ridge formation. On the other hand, remaining 4 cases showed a prominent movement of the soft palate which made contact with Passavant's ridge at the level where the ridge was formed, assuring velopharyngeal closure. Calnan et al.<sup>3)</sup> reported that the ridge had little importance in velopharyngeal closure because it is formed at lower position. However, present observation in 12 cases with prominent ridge revealed that velopharyngeal closure occurs in lower level than that of the normal subjects.

It was also demonstrated that the group with the prominent ridge exhibited sufficient movement of the lateral pharyngeal walls as compared with the group without the ridge. As Glaser<sup>4)</sup> reported Passavant's ridge was usually associated with active lateral pharyngeal wall motion, the Passavant's ridge appears to have a close relationship with mobility of lateral pharyngeal walls. Temporal analysis of the velopharynx revealed that the soft palate, lateral pharyngeal walls and Passavant's ridge move almost at the same speed. From these findings, it was indicated that the velopharyngeal closure took place by the simultaneous movements of these three components.

As to the formation of the ridge for different articulation, 7 cases showed the ridge for all sounds. Three cases who received intensive training of articulation



showed the ridge for all vowels, plosives and fricatives with the improvement of faulty articulation. Through cineradiographic study, Henningsson et al.<sup>5)</sup> (1986) reported that glottal articulation accompanied both poor velopharyngeal movement and reduced Passavant's ridge. Thus the ridge became prominent with improvement of faulty articulation, even if the ridge was not formed when the articulation was incorrect.

Honjo et al.<sup>6)</sup> disagreed with the concept that the ridge has an important role in compensating for velopharyngeal function, because of its inconsistency for different vowels and consonants. However subjects in their study had inadequate velopharyngeal closure with evident faulty articulation. On the other hand, present 12 subjects with the prominent ridge had competent or slight incompetent velopharyngeal function. This is the reason why their finding differs from ours. We have few report, however, which examined the Passavant's ridge in relation to the degree of velopharyngeal closure or difference of articulation. It seems important to observe the ridge from these view points, when we treat cleft palate cases with poor articulation and velopharyngeal incompetency.

#### SUMMARY

Passavant's ridge has a role to compensate the velopharyngeal closure in some cases, although small in numbers. The ridge is formed at the level slightly lower than that of normal velopharyngeal closure. Simultaneous movements of the soft palate, lateral pharyngeal walls and the Passavant's ridge constituted sphincter-like closure of the velopharynx. Their mobility was reduced for nasal sounds as compared with plosives and fricatives. Formation of the ridge was found to be improved as articulation improved by speech therapy.

#### REFERENCE

- 1) Skolnick, M. L., Shprintzen, R. J., McCall, G. N., and Rakoff, S.: Patterns of Velopharyngeal Closure in Subjects with Repaired Cleft Palate and Normal Speech: A Multi-view Videofluoroscopic Analysis. *Cleft Palate Journal*, 12: 369-376, 1975.
- 2) Tanokuchi, F., Sakai, S., Kawano, M. and Isshiki, N.: Articulation Training for Velopharyngeal Function Reinforcement. *Studia Phonologica XX*, 38-48, 1986.
- 3) Calnan, J.: The Error of Gustav Passavant. *Plast. & Reconstr. Surg.*, 13: 275-289, 1983.
- 4) Glaser, E. R., Skolnick, M. L., McWilliams, B. J. and Shprintzen, R. J.: The Dynamics of Passavant's Ridge in Subjects with and without Velopharyngeal Insufficiency—A Multi-View Videofluoroscopic Study. *Cleft Palate Journal*, 16: 24-33, 1979.
- 5) Henningsson, G. E. and Isberg, A. M.: Velopharyngeal Movement Patterns in Patients Alternating Between Oral and Glottal Articulation: A Clinical and Cineradiographical Study. *Cleft Palate Journal*, 23: 1-9, 1986.
- 6) Honjo, I., Kojima, M. and Kumazawa, T.: Role of Passavant's ridge in Cleft Palate Speech. *Arch. Otorhinolaryngol.*, 211: 203-208, 1975.
- 7) Beery, Q. G., Rood, S. R. and Schramm, V. L.: Pharyngeal Wall Motion in Prosthetically Magaged Cleft Palate Adults. *Cleft Palate Journal*, 20: 7-17, 1983.

(Aug. 31, 1987, received)