

## Uni-lateral Velar Palsy Connected with Microtia

Yoshio YAMAWAKI, Nobuhiko ISSHIKI, Yutaka HARITA,  
Tatsuzo TAIRA, Masaki SAWADA and Michio KAWANO

### INTRODUCTION

Congenital microtia, which is often accompanied by otocleisis, is relatively rare congenital anomaly which occurs every ten or eleven thousand births. At the Department of Plastic and Reconstructive Surgery in Kyoto University, the first auricular reconstruction with rib cartilage framework is performed on approximately

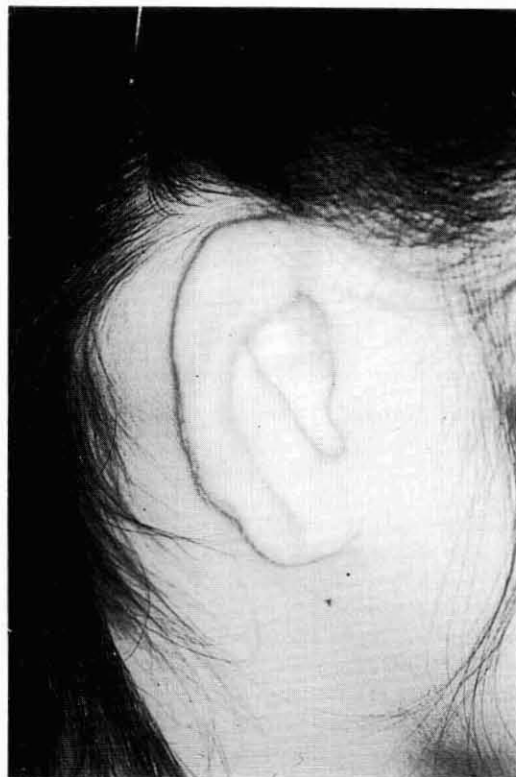

Fig. 1 Auricular Deformity, Grade I

Yoshio YAMAWAKI (山脇吉朗): Dept. of P.R.S., Toyooka Hosp.

Nobuhiko ISSHIKI (一色信彦): Department of Plastic and Reconstructive Surgery, Faculty of Medicine, Kyoto University

Yutaka HARITA (張田 裕): Dept. of P.R.S., Tenri Yorozu Hosp.

Tatsuzo TAIRA (平良達三): Dept. of P.R.S., Faculty of Medicine, Kyoto University

Masaki SAWADA (澤田正樹): Dept. of P.R.S., Hyogo Prefecture, Amagasaki Hosp.

Michio KAWANO (川野通夫): Department of Otorhinolaryngology, Faculty of Medicine, Kyoto University

10 cases every year.

Among these cases, we have found several cases of uni-lateral velar palsy, e.g., asymmetrical motion of velum. The asymmetry is more marked when microtia is a part of the first and the second Branchial syndrome than otherwise. As the movement of the velum plays an important role in velopharyngeal closure, velar palsy can cause velopharyngeal incompetence, consequent nasality and communication disorder. This report deals with the velopharyngeal function chiefly the velum mobility in the cases of unilateral microtia.

#### SUBJECTS AND METHOD

The subjects of this study include 24 patients who underwent the first stage auricle reconstruction at our clinic. Microtia is anatomically classified into three grades. Grade I represents the state of a smaller auricle than the normal size (Fig. 1). When there exists an eminence equivalent to helix, it is classified into Grade II (Fig. 2). In Grade III, the deformity is the severest, and only a small or no remnant is seen (Fig. 3). Among the 24 cases, there were 2 cases of Grade I, 9 cases of Grade II, and 13 cases of Grade III. Peroral inspection was made on all of the subjects to observe velum movement. Nasoendoscopic examination was done on 21 subjects, and fluorovideoscopic examination on 14 subjects. On the

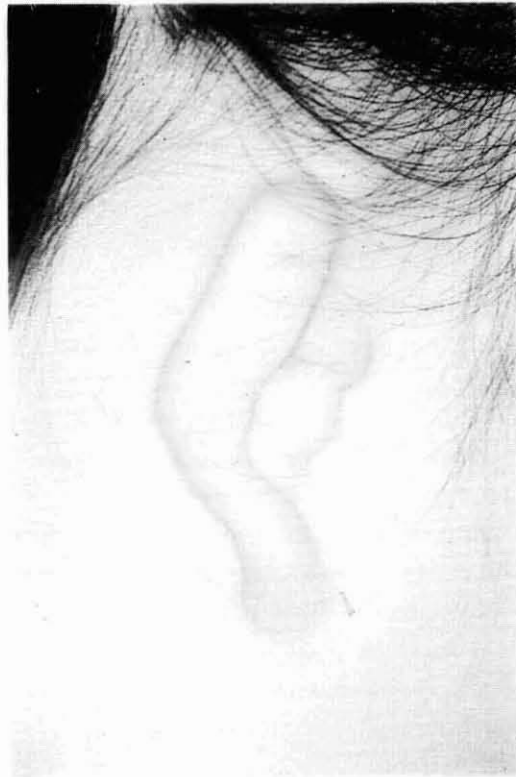

Fig. 2 Auricular Deformity, Grade II

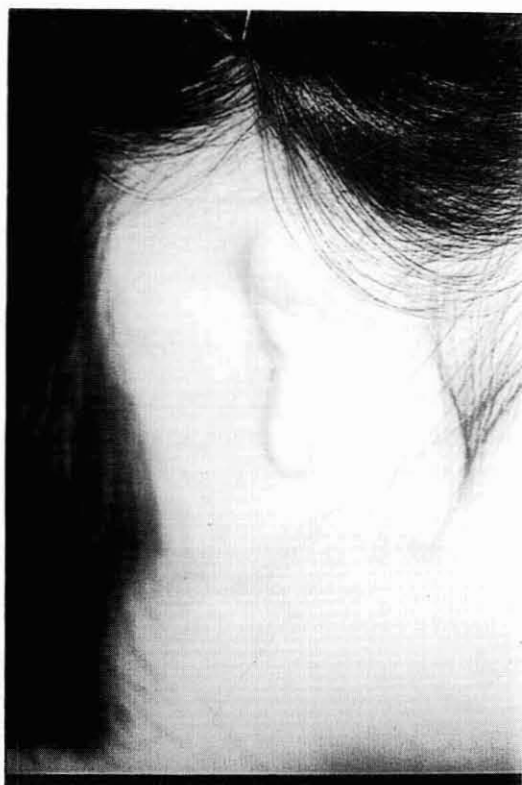

Fig. 3 Auricular Deformity, Grade III

basis of these examinations, overall assessments were made on the velum mobility and velopharyngeal function.

#### RESULTS

On inspection, 9 subjects (38%) showed almost normal velar elevation on production of vowel [a:], and no asymmetrical movement was seen (Fig. 4). However, in 15 subjects (62%), the velum elevated toward the normal auricle side (Fig. 5). Among these 15 subjects, 14 subjects (58%) showed distinctive unilateral velar paralysis with the uvula almost touching the palatopharyngeal arch of the normal side (Fig. 6). Besides, only one of the 24 subjects showed the contrary movement in which the uvula elevated toward the abnormal side. There exists some correlation between the degree of malformation and that of velar paralysis, that is to say, the severer the deformity, the more distinctive the asymmetrical movement (Fig. 7).

On lateral fluorovideoscopic examination, a knee-shaped velar elevation is seen in normal subjects. However, such velar elevation was not seen in 2 out of 7 Grade II subjects, and 4 out of 7 Grade III subjects (Fig. 8).

The anteroposterior fluorovideoscopic examination revealed that 2 out of Grade III subjects showed asymmetrical lateral wall movement, that is, the mobility

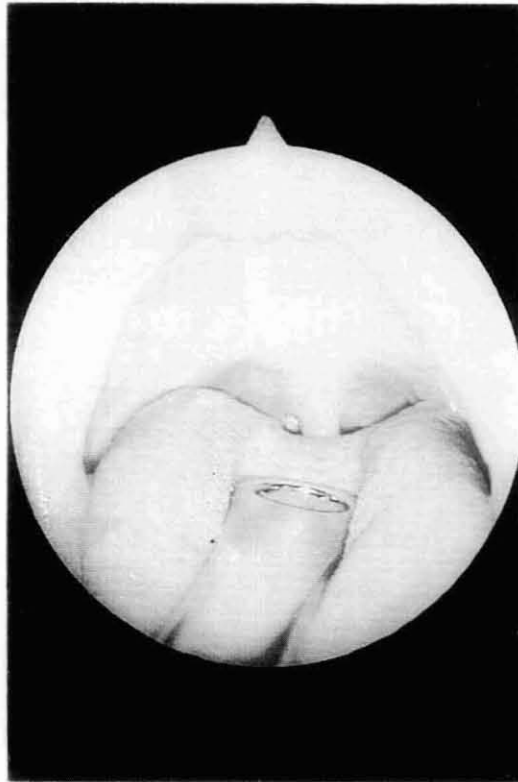


Fig. 4 Normal velar elevation

of the lateral wall is smaller on the abnormal side than on the normal side (Fig. 9, 10). On velar elevation in the normal, a bulging is always noted endoscopically at the midportion of the velum, indicating the contraction of the uvular muscle. In these patients with microtia, however, 14 out of 21 did not show the bulging, but rather a flat or depressive contour there instead (Fig. 11). Moreover, 3 subjects (14%) showed slight velopharyngeal incompetence on fiberoptic examination (Fig. 12), though no nasality was perceived auditorily. No correlation was noted between the velopharyngeal function and the degree of malformation (Fig. 13).

#### DISCUSSION

Although microtia had been considered to be an independent congenital anomaly, recent trend is that it is regarded as one of the symptoms in hemifacial microsomia. Hemifacial microsomia is a morphological or embryological disorder, involving the organs derived from the first and the second branchial arches.

Since Gortin suggested this concept in 1964, many researchers have discussed about its symptoms and classification. In 1977, Luce studied velopharyngeal function in 18 subjects with microtia by means of fluorovideoscopy, and reported that one third of the subjects showed velopharyngeal incompetence. Studying on the

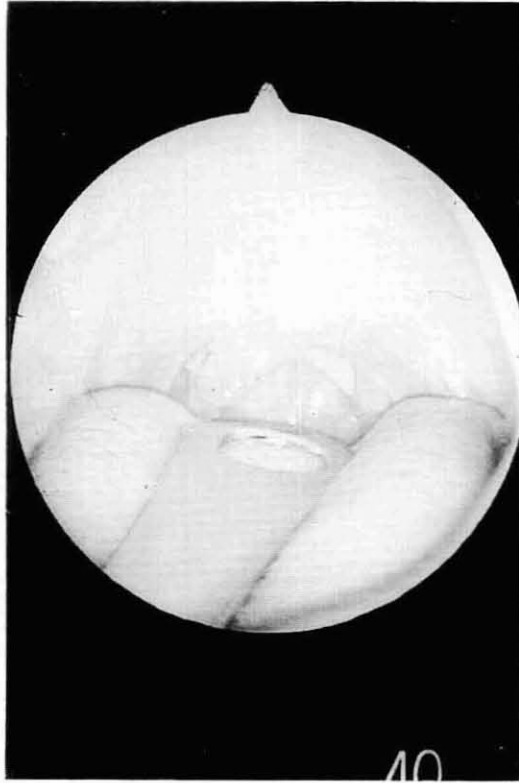

Fig. 5 Velar traction toward the normal side

velopharyngeal and velar movement in 19 subjects with microtia, Dellon (1983) reported that the hemipalatal palsy are high incidence among the microtia patients, and this fact, supported of the hypothesis that the levator veli palatini muscle has multiple cranial nerve innervation, and is derived, at least in part from the first and second branchial arch. In our study on velopharyngeal dynamics in microtia, reduced mobility of the velum on the involved side was found much more frequently (58%) than expected. These reduced mobility was associated in most of the cases with a flat or depressive contour of the velum in the midline as observed from the nasal side. The characteristic contour of the velum is such as that frequently found in case of submucous cleft palate or congenital velopharyngeal incompetence. In the latter, such velar dynamic deformity has been attributed to the absence or hypogenesis or denervation of uvula muscle and levator veli palatini muscle. In other words, it can be said that hemifacial microsomia not infrequently presents reduced velar mobility on the involved side. A tendency is noted that the severer the auricular deformity, the more marked the velar immobility.

One exceptional case showed the reduced velar movement on the intact side, the reason for which is unknown. Further studies, including the electromy-

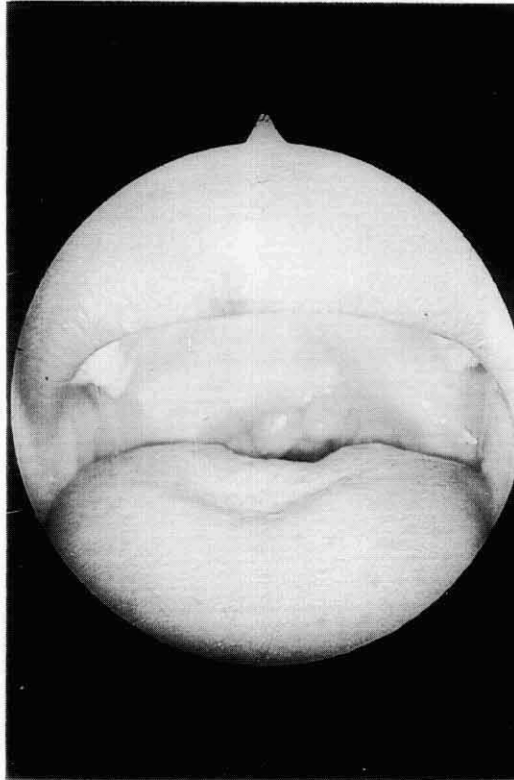


Fig. 6 Distinctive velar paralysis

graphical and histological examinations, are needed to find out the factors responsible for the velopharyngeal incompetence in hemifacial microsomia.

(Aug. 31, 1987, received)

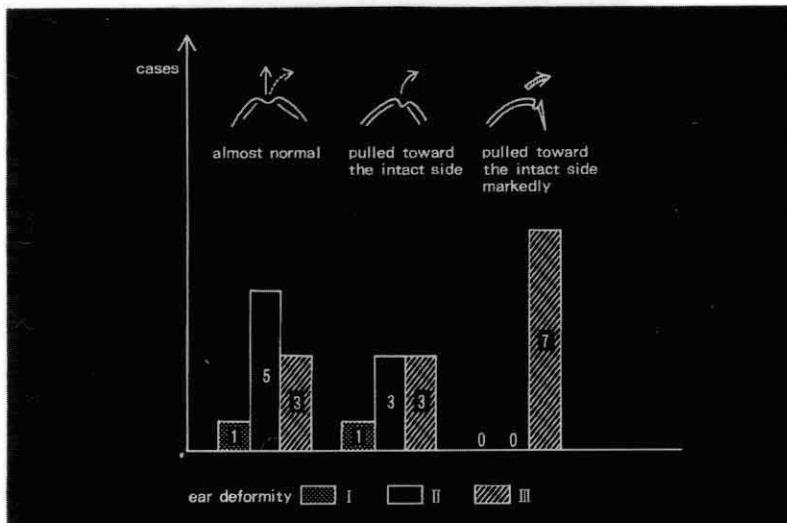


Fig. 7 Correlation between the degree of ear malformation and that of velar paralysis

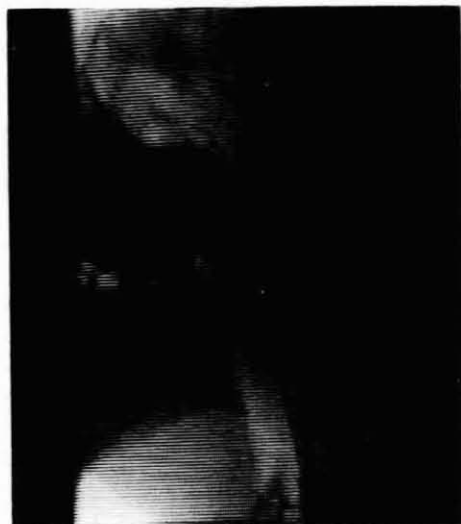

Fig. 8 No kneeshaped velar elevation on speech production (lateral Fluorovideoscopic view)

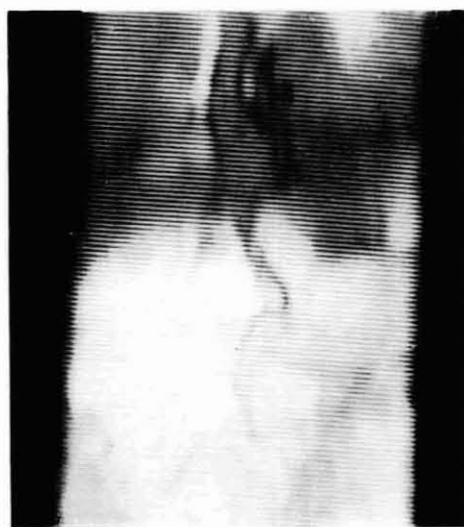

Fig. 9 Asymmetrical lateral wall movement (frontal fluorovideoscopic view)

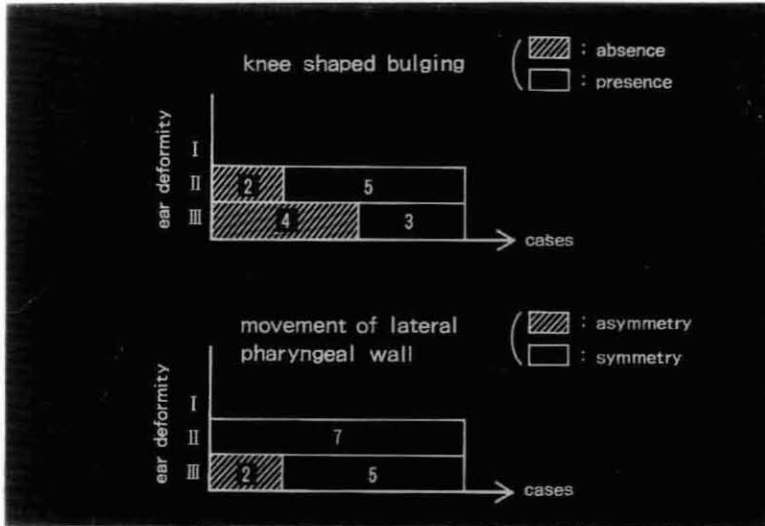


Fig. 10 Correlation between the degree of malformation and the fluorovideoscopic findings

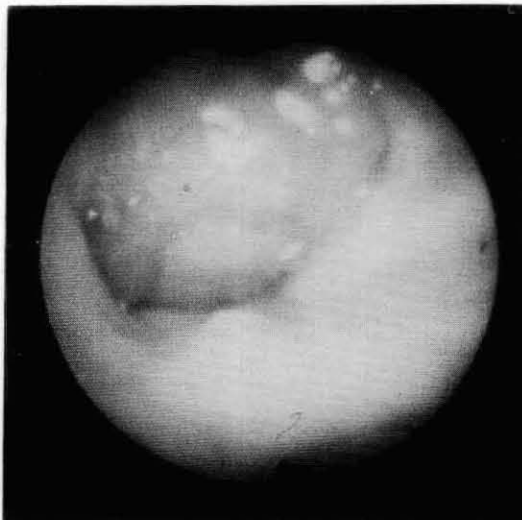


Fig. 11 No bulging at the mid-portion of the velum during phonation



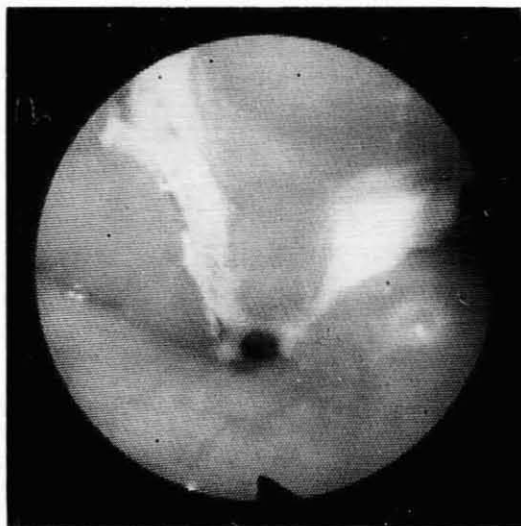


Fig. 12 A case of velopharyngeal incompetence

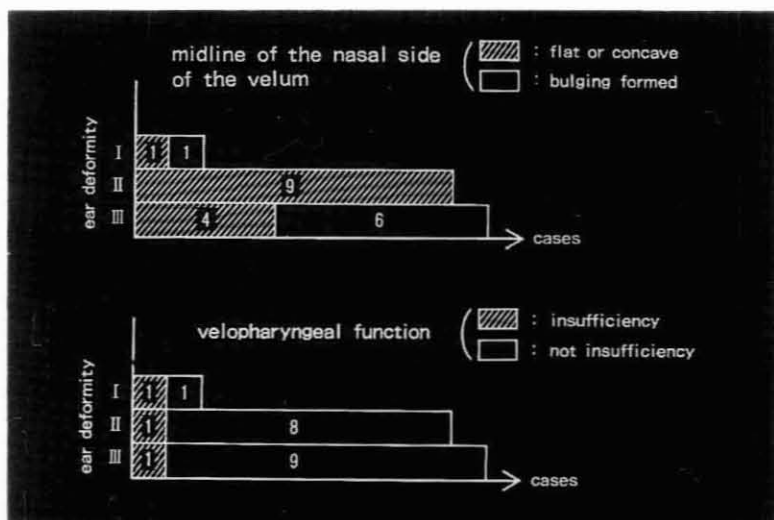


Fig. 13 No correlation between the velopharyngeal function and the degree of malformation