

Histoanatomical Studies of the Intrinsic Laryngeal Muscle

Hiroyuki ITO

A considerable amount of research has been reported on the gross and microscopic studies of intrinsic laryngeal muscle. The suggestion that the vocal muscle fibers do not run parallel to the vocal fold but the muscle consists of two complicated muscle bundles which cross each other, was first made by K. Goerttler in 1950. Goerttler named these two separated muscle bundles, M. thyrovoacalis and M. Aryvoacalis. Since Goerttler's paper, further information on this problem has been provided by Wustrow, Behringer, Ruede etc. Wustrow demonstrated that the thyreo-arytenoid muscle consists of two portions. In the abducted position of the fold, the portio thyreo-vocalis runs directly backwards from the thyroid to the vocal process of the arytenoid. The second portion arises centrally and more deeply from the inner surface of the thyroid cartilage and crosses under to insert into the muscular process of arytenoid. This is portio thyreomuscularis. In the adducted position, as a result of rotation of the arytenoid cartilage, both portions of thyreoarytenoid muscle run parallel to each other and parallel to the margin of the vocal fold. Wustrow's finding thus confirms the old established view of longitudinal course of the thyreo-arytenoid muscle. Differences of opinions concerning the structure of the vocal muscle seem to justify a further precise work on this problem. The work reported here is systematic observation of detailed structure of intrinsic laryngeal muscles and above mentioned problem is discussed.

For this purpose, normal larynx of human adult, suckling, foetus were examined first, and as animal materials, normal larynx of adult monkey, dog, cat, rabbit, cow and pig were used. After fixation, decalcification and embedding, horizontal, sagittal and frontal section of larynx was serially made in 20-30 μ of thickness. Using various techniques of staining, the course of muscle fibers, connection of muscle fibers to the vocal ligament, motor nerve supply, and motor nerve end-plate were observed.

The vocal muscle of man differentiated into two sets of muscle bundles in accordance with the course of muscle fibers in the horizontal section. One of these ran from inner surface of the thyroid cartilage parallel to the vocal ligament and attached to the vocal process and the fovea oblonga of arytenoid. The other set of muscle fiber arose from the vocal process and the fovea oblonga attaching to whole length of the vocal ligament. A great many fibers of this muscle

bundle ended at the portion of anterior 1/3 or posterior 1/3 of the vocal ligament. Only a few fibers terminated at the midportion of the ligament. Inserting into elastic ligament, each muscle fiber welded into the vocal ligament, as if the vocal ligament was a tendon of these muscle fibers. Microscopic pictures of Fig. 1, 2, 3, illustrated this firm connection. Muscle fibers of above mentioned two sets of bundles crossed each other. This crossed muscle fibers is shown in Fig. 4.

Through the frontal sections, it was noted that transverse section of vocal muscle directed towards the free edge of the vocal cord, or the conus elasticus of subglottic space, whereas transverse section of the external thyreoarytenoid muscle directed towards false vocal cord. Remarkable difference in arrangement of vocal muscle and external thyreoarytenoid muscle fiber was noted in the section from the middle to the posterior end of the vocal cord. Frontal section through the vocal cord is illustrated in Fig. 5.

In the saggital sections, it was known that the vocal muscle existed between inner surface of the thyroid cartilage and anterior surface of the arytenoid cartilage. In this section, the vocal muscle was noted to be consisted of two portions of muscle bundle which was observed in frontal section. Muscle fibers which originated from the thyroid cartilage ran parallel to the base of ventricle and the other fibers which arised from anterior surface of the arytenoid directed towards the ventricular base. Termination at the thyroid cartilage was not remarked among the later muscle fibers. The arrangement of muscle fibers in this section is shown in Fig. 6.

According to author's observation, the vocal muscle can be divided into two sets of muscle bundle, one of which is called *pars thyreoarytenoideus* and the other is called *pars aryvocalis*. The *pars thyreoavocalis* shown by Goerttler was not recognized in any section of the larynx.

The trunk of recurrent nerve, external branch of superior laryngeal nerve, and internal branch of inferior laryngeal nerve mainly consisted of myelinated nerve fiber, and contained a few unmyelinated fibers. The course of nerve fibers in the vocal muscle, and minute structure of endplate which innervated different portion of muscle bundle showed no difference. The external branch of superior laryngeal nerve consisted of myelinated nerve fibers was illustrated in Fig. 9.

Investigations on the development of the vocal muscle and the external thyreoarytenoid muscle in embryonic life were made in 38 foetus from fifth month to ninth month using a planimetical method. An area of transverse section of both muscle grew larger six times during 5 months, while the same degree of growth took place in the frontal and saggital section. On the basis of this result, it is reasonable to presume that the growth of intrinsic laryngeal muscle does not depend on increase in number but increase in volume of muscle fiber, because of the ratio of growth in both muscle fiber and bundle was in a same degree.

Before third month of embryonic life, formation of the vocal muscle bundle was not recognized. After the end of third month, the formation of vocal muscle bundle was noted and its histological finding developed to have close similarity to adults. A comparison of the vocal cord of embryos and adults was made and the differences between the embryonal and the adult vocal cord was summarized as follows.

1) The angle of vocal cord edge formed by ventricular base and subglottic space ranged from 70° to 110° in the adult larynx, while in the embryonal larynx this value ranged from 90° to 110° . Therefore the embryonal vocal cord had more sharp edge.

2) The entire mucous membrane of embryonic larynx was a columnar ciliated epithelium, while the suckling and adult vocal cord was covered by a stratified squamous epithelium.

3) In the embryonal larynx, the thickness of subepithelial mucous layer of both ventricular base and subglottic space was approximately equal. In suckling larynx, subglottic space had more thick subepithelial mucous layer especially anterior half of the vocal cord.

In the adult larynx, subepithelial mucous layer which covered above two area conspicuously differed in its thickness. Subepithelial mucous layer of subglottic space showed from 1.5 to 4 times of thickness comparing with that of ventricular base.

5) The thickness of mucous membrane which lined free edge of the vocal fold had quite uniformity in any portion of the embryonic vocal cord. In the adult vocal cord, the thickness varied with the portion of the cord. In anterior $1/3$ of the cord, the thickness was twice comparing with the thickness in mid $1/3$ and posterior $1/3$.

These differences which lie in foetal and adult larynx are reasonably reduced to voiceless life of embryo and voice production after birth.

Observations on the animal vocal muscle are briefly mentioned. Animals of which vocal muscle were divided into two sets of muscle bundles were human, monkey and dog. The vocal muscle fibers inserted into the vocal ligament were recognized in human, monkey, dog, cow and pig. Especially cow and pig had not parallel muscle fibers with the vocal ligament. Every vocal muscle fiber of these two species of animals arised from the arytenoid and inserted into the vocal ligament while the vocal muscle fibers of rabbit and cat ran parallel to the vocal ligament without any insertion into the ligament. An angle of the free vocal cord edge was more sharp in monkey, dog and cat than in human. The thickness of mucous membrane which covered ventricular base, margine of the fold, and subglottic space was thicker in this order.

K. Goerttler put forth the view that the vocal muscle consists of a complicated system of muscle fibers which is divided into two sets of muscle bundle crossing each other.

Controversy has continued as to minute structure of the vocal muscle since Goerttler's paper. In this paper, the new concept on the structure of the vocal muscle is proposed. According to author's investigation, the vocal muscle can be divided into two portion of bundles which cross each other. They are named pars thyreoarytenoideus and pars aryvocalis respectively, but Goerttler's pars thyreoarytenoideus is not noted in any section of the vocal cord. This conception are confirmed by the observation on the embryonal vocal muscle and animal vocal muscle. The differences which exist in the larynx especially in the vocal cord of man and other various animals are briefly but clearly demonstrated.

Fig. 1. 2. 3. show that the vocal muscle fibers insert into the vocal ligament. Adult larynx.

Fig. 1. H.E. staining. 50 \times . Posterior portion of the cord.

Fig. 2. H.E. staining. 50 \times . Anterior portion of the cord.

Fig. 3. Weigert's elastic tissue staining. 200 \times .

Fig. 4. Crossing of two muscle bundle system. H.E. staining 400 \times .

Fig. 5. Frontal section of adult vocal cord. H.E. 200 \times .

Fig. 6. Saggital section of adult vocal cord. H.E. 200 \times .

The course of pars aryvocalis and its termination at the vocal ligament are illustrated.

Fig. 7. Horizontal section 7th months embryonal vocal cord. H.E. 50 \times .

Fig. 8. Horizontal section through the vocal muscle of one year and two months suckling.

E.H. Staining 200 \times . Showing the crossing of two muscle bundle system.

Fig. 9. External branch of superior laryngeal nerve. Showing myelinated nerve fibers. Yagi's staing method. 200 \times .

Fig.10. End-plate in external thyreoarytenoid muscle.

Suzuki's modification of Bielschowsky's method. 50 \times .



Fig. 1

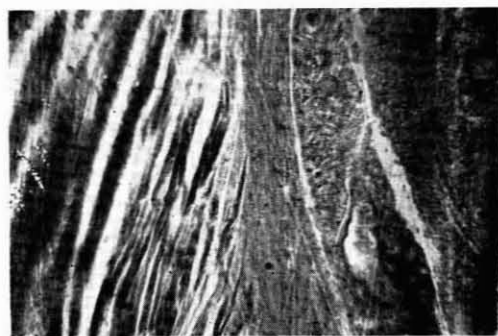

Fig. 2




Fig. 3



Fig. 4

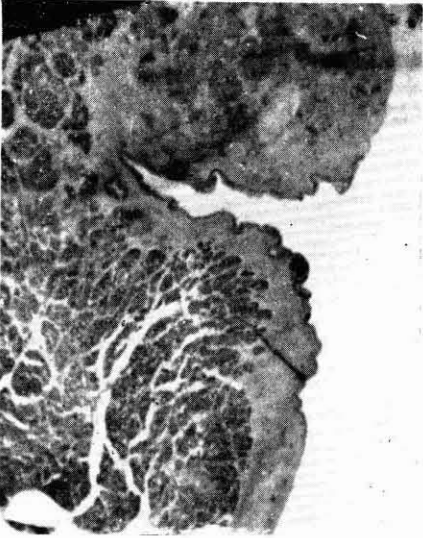


Fig. 5

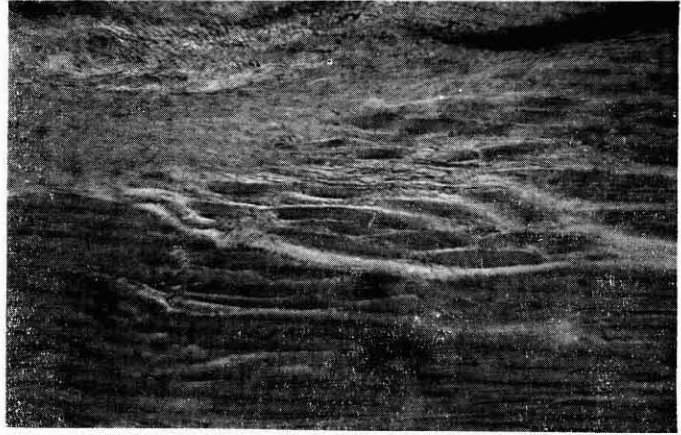

Fig. 6

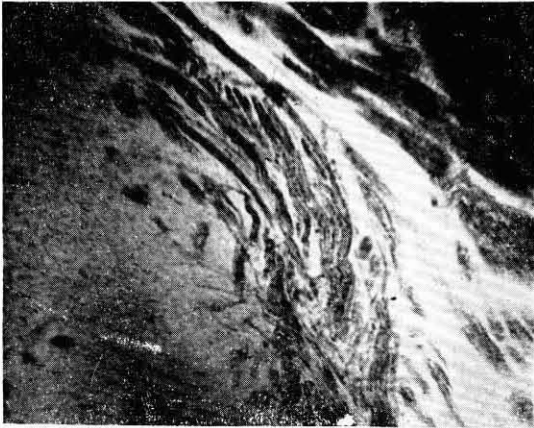


Fig. 7

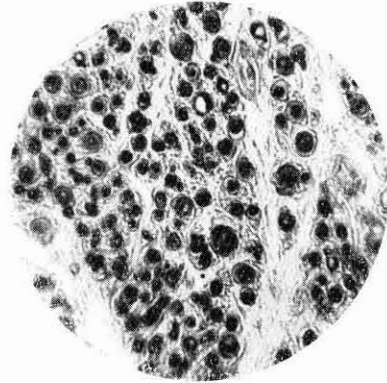


Fig. 9

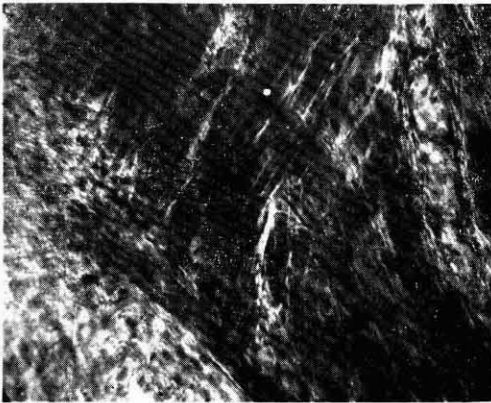


Fig. 8



Fig. 10