

A CASE OF ORBITAL METASTASIS FROM PROSTATIC CARCINOMA AS AN INITIAL SYMPTOM

Shinzo ISSHIKI, Shuko CHO, Daisuke MATSUNO,
Naohide SATO and Yuzo FURUYA

The Department of Urology, Teikyo University Chiba Medical Center

Orbital metastasis caused by prostate cancer is rare. We report a case of prostate cancer diagnosed from the initial ocular signs with complaints of decreased vision and exophthalmos. The orbital tumor was surgically removed and endocrine therapy was performed subsequently. Metastatic carcinoma of the prostate should be considered in the elderly male with exophthalmos.

(Hinyokika Kiyo 53 : 193-195, 2007)

Key words : Prostate cancer, Orbital metastasis

INTRODUCTION

Orbital metastasis caused by prostate cancer is rare. We report a case of prostate carcinoma metastasizing to the left orbital bone. Pathological findings of the orbital tumor confirmed that the origin of the tumor was the prostate.

CASE REPORT

A 70-year-old man with complaints of decreased vision and swelling of left eye one month in duration visited the ophthalmological department of our hospital. Physical examination demonstrated left eye exophthalmos. Magnetic resonance imaging (MRI) demonstrated a left orbital mass (Fig. 1). The tumor was approximately 3 cm in diameter. The tumor was surgically removed at the neurosurgical department. After the surgery, ophthalmological symptoms were resolved. Pathological findings suggested that the primary focus of the tumor was the prostate. Then the patient was referred to our department. Serum total PSA measured with Tandem-R before digital rectal examination (DRE) was 163 ng/ml. DRE revealed an enlarged, firm prostate gland. Bone scintigraphy suggested multiple metastases (Fig. 2). Pathological examination confirmed the

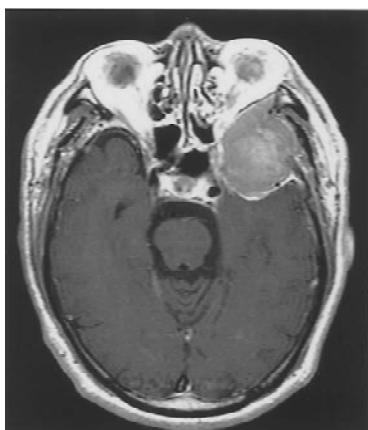


Fig. 1. Magnetic resonance imaging demonstrates 3 cm mass in left orbit.

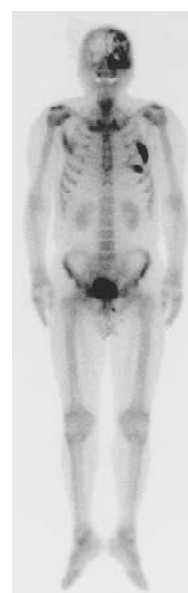


Fig. 2. Bone scan demonstrates multiple bone metastases.

diagnosis of adenocarcinoma of the prostate (Gleason 4 + 3). Orchiectomy was performed simultaneously and bicaltamide was administered orally. Serum PSA decreased below 4.0 ng/ml within 3 months. The patient had no evidence of PSA biochemical failure and ophthalmological symptoms have not reappeared for 12 months.

DISCUSSION

Osseous metastases are the most common form of distant spread from carcinoma of the prostate. Orbital metastases caused by prostate cancer are rare; only 50 cases have been reported in the world literature and 9 cases have been reported in Japan^{1,2)}. Moreover, the report of prostate cancer diagnosed from initial orbital metastases is rare with only one case has been reported in Japan³⁾. Tumors metastatic to the orbit comprise 12% of all orbital malignancies⁴⁾. Only 3.2% of all metastatic orbital tumors in Japan were from prostate carcinoma⁵⁾. The prognosis of these patients seems to depend on the effectiveness of hormonal treatment⁶⁾.

Endocrine treatment and palliative external beam radiotherapy remain the standard treatment for restoration of vision and remittance of orbital symptoms¹⁾. In the present case decompressive surgery was performed because a precise diagnosis was not made. Decompression improved the optic functions and there have been no ophthalmological symptoms with the endocrine treatment. However, we could not comment on the benefit of the initial decompressive surgery on the prognosis of this patient. With the rapid increase in prostate carcinoma in Japan, metastatic carcinoma of the prostate should be considered in the differential diagnosis in the elderly male with ocular signs.

REFERENCES

- 1) Gonzalez CM, Kuzel T and Carter MA : Metastatic adenocarcinoma of the prostate to the orbit as a presenting symptom. *J Urol* **157** : 625, 1997
- 2) Inagaki T, Ebisuno S, Miyai M, et al. : A case of prostate cancer metastasizing to the orbit. *Int J Urol* **6** : 114–115, 1999
- 3) Sunaoshi K, Tanaka T, Yanase M, et al. : A case of prostate cancer detected by intraorbital metastasis. *Jpn J Urol Surg* **19** : 179–181, 2006
- 4) Goldberg RA, Rootman J and Cline RA : Tumors metastatic to the orbit : a changing picture. *Surv Ophthalmol* **35** : 1–24, 1990
- 5) Amemiya T, Hayashida H and Dake Y : Metastatic orbital tumors in Japan : a review of the literature. *Ophtalmic Epidemiol* **9** : 35–47, 2002
- 6) Tertzakian GM, Herr HW and Mehta MB : Orbital metastases from prostatic carcinoma. *Urology* **19** : 427–429, 1982

(Received on September 4, 2006)
(Accepted on November 12, 2006)

和文抄録

眼窩転移で発見された前立腺癌の1例

一色 真造, 趙 秀孔, 松野 大輔
佐藤 直秀, 古谷 雄三

帝京大学ちば総合医療センター泌尿器科

70歳, 男性. 左眼の視力低下, 眼球の突出を認め, 頭部 MRI 検査にて左眼窩腫瘍を認めた. 脳外科にて左眼窩腫瘍部分切除術を施行した. 病理組織学的に前立腺癌の眼窩転移と診断され, 前立腺生検にて中分化腺癌を確認し, 内分泌療法を施行中である. 前立腺癌

の眼窩転移は非常に稀である. 眼窩転移巣の症状が契機となって発見された前立腺癌は本邦で1例報告されているのみである.

(泌尿紀要 **53** : 193-195, 2007)