TRANSCATHETER ARTERIAL EMBOLIZATION WITH N-BUTYL-2-CYANOACRYLATE (HYSTOACRYL®) IN TWO TREATMENTS FOR HUGE RENAL ARTERIOVENOUS MALFORMATION

Yasuaki Kubota[1], Tomohiro Tsuchiya[1], Shingo Kamei[1], Yoshito Takahashi[1], Hidetoshi Ehara[1], Takashi Deguchi[1], Satoshi Goshima[2] and Masayuki Kanematsu[2]

[1]*The Department of Urology, Gifu University School of Medicine and Graduate*
[2]*The Department of Radiology, Gifu University School of Medicine and Graduate*

We report a case of huge renal arteriovenous malformation treated with superselective endovascular embolization in two treatments using N-butyl-2-cyanoacrylate (Hystoacryl®).

(Hinyokika Kiyo **53** : 307–310, 2007)

Key words : AVM, Embolization, N-butyl-2-cyanoacrylate

INTRODUCTION

Transcatheter embolization is the preferred treatment of arteriovenous malformation (AVM). While there are several embolic materials, N-butyl-2-cyanoacrylate is considered the optimal embolic agent for AVM embolization because of its ability to permeate vascular occlusions and because it can be used in huge AVMs. Here we report a case of huge renal arteriovenous malformation treated with superselective endovascular embolization in two treatments using N-butyl-2-cyanoacrylate.

CASE REPORT

A 40-year-old female was taken to the hospital for bladder tamponade. She had a history of repeated gross hematuria of unknown cause. When she noticed gross hematuria, she visited a urologist who examined her urinary tract.

The physical examination was normal and abdominal bruit was not detected. Laboratory data were normal except for low hemoglobin (Hb 11.6 g/dL). Urinalysis showed multiple red blood cells in all fields. Cystoscopy demonstrated bloody urine from the right ureteral orifice. Abdominal 3-dimensional computed tomography (CT) disclosed a huge arteriovenous malformation in the lower pole of the right kidney with early filling of the renal vein and the inferior vena cava (Fig. 1).

She was admitted to our hospital for embolization of the huge renal arteriovenous malformation. Percutaneous transfemoral catheterization using Seldinger's method was employed and right renal angiography was performed. Right renal artery bifurcates and the main feeding artery into the AVM was a caudal branch. AVM was diagnosed as high flow type from the early filling of the renal vein (Fig. 2). A cephalic branch from the caudal renal artery was superselectively catheterized to the interlobar level with a microcatheter. Embolization with absolute alcohol into the nidus was performed twice ; however, the treatment failed because of large amounts of blood flow. Embolization into the

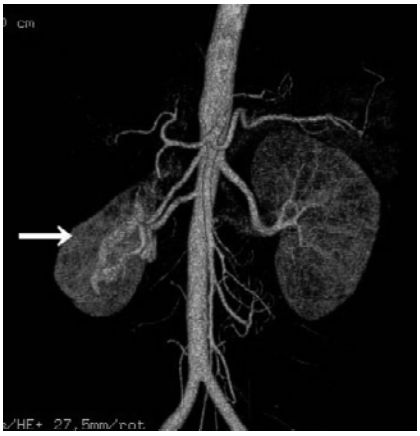

Fig. 1. Abdominal 3-dimentional CT shows huge arteriovenous malformation in the lower pole of the right kidney.

Fig. 2. Right renal angiography shows AVM in the lower pole of the right kidney with early filling of the renal vein.

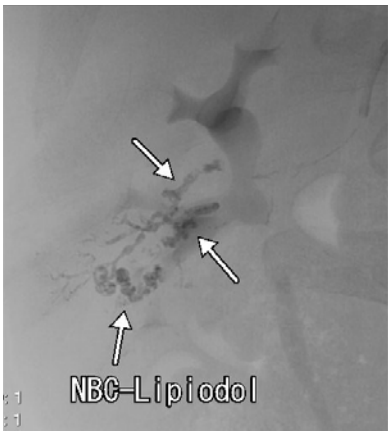

Fig. 3. Postembolization angiography confirms complete occlusion of the whole nidus.

nidus was performed alternatively with a mixture of 0.5 ml N-butyl-2-cyanoacrylate and 1.0 ml lipiodol. Post-embolization angiography showed occlusion of the cephalic region of the nidus. Because of the large size of the AVM and severe backache, embolization was finished without occlusion of the caudal lesion.

A week later, embolization into the caudal lesion was performed. In the same way as in the previous procedure, angiography to the caudal artery was performed. Catheterization into the caudal lesion with the microcatheter was difficult; however, using a 5Fr Cobra-guiding catheter made it possible to select the feeding artery. Embolization into the caudal nidus was performed with a mixture of 0.5 mL N-butyl-2-cyanoacrylate and 1.5 mL lipiodol. Postembolization angiography confirmed complete occlusion of the entire nidus (Fig. 3). Postoperative abdominal CT showed that a fourth volume of the right kidney was infarct. Right backache was controlled with administration of epidural anesthesia. The postoperative course was uneventful. At 3-months follow-up, the urine was free from red blood cells and MRI showed no recanalization in the right kidney.

DISCUSSION

Renal arteriovenous malformation (AVM) is rare; however, with the development of radiography, the number of reported cases of renal AVM has increased. Some AVM cases might have been missed with a differential diagnosis of hematuria. Renal AVM is generally classified as either congenital or acquired. The causes of acquired AVM include trauma, surgery, tumor and inflammation. Percutaneous renal biopsy is the most common known cause of acquired renal arteriovenous fistula. Another classification from the view of arteriogram has divided AVM into two groups. One is called the cirsoid type, which is characterized by multiple communications called niduses between arteries and veins without an intervening capillary bed. The other is the anuerysmal type, which has fistulas appearing as solitary communications between the artery and vein. The cirsoid type is characterized by a high incidence of gross hematuria. They cause hematuria and are associated with hypertension. Diagnostic evaluation of patients with microscopic hematuria also may lead to the discovery of an AVM. In contrast, the aneurismal type is characterized by cardiovascular signs, such as abdominal bruit, hypertension and congestional heart failure.

Our case was of the cirsoid type with gross hematuria, resulting in bladder tamponade. The fact that on a previous visit to a urologist no AVM was suggests that AVM of the right kidney had been growing for several years.

Angiography was thought to be the standard for the clinical diagnosis of AVM. However, several reports have confirmed the diagnostic usefulness of 3-dimension CT and MRI[1]. Both can lead to an accurate diagnosis of renal AVMs. Likewise, several cases have been reported in which a mass lesion was correctly identified as a renal AVM by the use of color-duplex Doppler ultrasound studies. In the future, a noninvasive means will be favored for evaluating renal causes of hematuria.

The treatment of renal AVMs depends on size and etiology. Surgery used to be indicated for larger or symptomatic lesions. Since renal artery embolization was first introduced in 1973, the applications of renal intervention have rapidly expanded. Transcatheter embolization, a minimally invasive technique, is the preferred first technique for treatment of AVMs. Embolic materials used in renal vascular lesions include absolute ethanol, ethibloc, gelfoam and coils. Each of these materials has its pros and cons (Table 1)[2–4]. However, several cases in which occlusion with these materials was incomplete and therefore required open surgery.

N-butyl-2-cyanoacrylate is a tissue-adhesive material that generally has been used to close small surgical wounds. N-butyl-2-cyanoacrylate, which absorbs water from surrounding tissues and polymerizes, is considered to be the optimal embolic agent for AVM embolization because of its ability to permeate vascular

Table 1. Advantages and disadvantages of embolic agents

Agent	Advantage	Disadvantage
Gelform	Availability in a variety of sizes easy handling	Recanalization
Steel coil	Precise positioning	Collateralization
	High radiopacity	Limitation of the future access
Ethanol	Occlusion at the capillary level	Acute systemic toxicity
	Less recanalization	Difficulty for extreme blood flow
N-butyl-2 cyanoacrylate	High curative potential	Considerable skill required

occlusions and is even applicable in huge AVMs[5–8]. Moreover, N-butyl-2-cyanoacrylate is the only material that can embolize AVM like a mold and when mixed with lipiodol can make the polymerization visible fluoroscopically. The polymerization time can be adjusted by the concentration of mixed lipiodol.

N-butyl-2-cyanoacrylate has been reported to be used in the closure of urinary fistula after partial nephrectomy and in the treatment of high flow priapism[9]. The frequency of use of N-butyl-2-cyanoacrylate is increasing because of its rapid polymerization and effectiveness, but gluting of the catheter tip might happen as a complication of embolization with N-butyl-2-cyanoacrylate. To avoid this complication, one has to pay special attention and retrieve the catheter before the glue is polymerized. Additionally there might be a possibility of occlusion of normal arterial branches.

Performing the microcatheter technique with N-butyl-2-cyanoacrylate requires great skill. Indications for surgical therapy have become more restricted as the ability to treat renal AVMs with angiographic embolization has improved.

REFERENCE

1) Ishikawa T, Tamada H, Inoue T, et al. : Diagnostic availability of magnetic resonance angiography (MRA) in a case of cirsoid-type renal arteriovenous fistula. Acta Urol Jpn **49** : 47–49, 2003
2) Nakai M, Nakamura N and Suzuki Y : Transcatheter arterial embolization with n-butyl 2-cyanoacrylate (hystoacryl) for renal arteriovenous malformation : case report. Acta Urol Jpn **49** : 51–53, 2003
3) Chatziioannou A, Mourikis D, Kalaboukas K, et al. : Endovascular treatment of renal arteriovenous malformations. Urol Int **74** : 89–91, 2005
4) Yamakado K, Nakatsuka A, Tanaka N, et al. : Transcatheter arterial embolization of ruptured pseudoaneurysms with coils and n-butyl cyanoacrylate. J Vasc Interv Radiol **11** : 66–72, 2000
5) Defreyne L, Govaere F, Vanlangenhove P, et al. : Cirsoid renal arteriovenous malformation treated by endovascular embolization with n-butyl-2-cyanoacrylate. Eur Radiol **10** : 772–775, 2000
6) Cromwell LD, Freeny PC, Kerber CW, et al. : Histologic analysis of tissue response to bucrylate-pantopaque mixture. AJR **147** : 627–631, 1986
7) Nagata M, Goto T and Kurooka Y : Successful transcatheter arterial embolization therapy using NBCA (N-butyl-2-cyanoacrylate) for arteriovenous malformation in the kidney : a case report. Renal Transplant・Vasc Surg **15** : 56–59, 2003
8) Nishihara K, Kawagoe N, Matsuoka K, et al. : Transcatheter arterial embolization with N-butyl 2-cyanoacrylate (NBCA) for renal arteriovenous malformation : a case report. Nishinihon J Urol **67** : 132–135, 2005
9) Alvarez Gonzales E, Pamplona M, Rodriguez A, et al. : High flow priapism after blunt perineal trauma : resolution with bucrylate embolization. J Urol **151** : 426–428, 1994

(Received on October 11, 2006
Accepted on December 28, 2006)

和文抄録

N-butyl 2-cyanoacrylate（hystoacryl®）にて2期的に塞栓術を要した巨大腎動静脈奇形の1例

久保田恵章[1]，土屋　朋大[1]，亀井　信吾[1]，江原　英俊[1]
高橋　義人[1]*，出口　　隆[1]，五島　　聡[2]，兼松　雅之[2]
[1]岐阜大学医学部臓器病態講座泌尿器病態学，[2]岐阜大学医学部放射線科

症例は40歳，女性．膀胱タンポナーデを主訴に近医受診した．膀胱鏡にて右尿管口からの出血を認めた．造影 3D-CT 所見から右腎中央から下極に渡る 3×4 cm の巨大な腎動静脈奇形と診断した．造影にて早期から流出静脈が認められ，high flow type と診断した．無水エタノールでの塞栓は無効であったため，N-butyl 2-cyanoacrylate（hystoacryl®）を用いて，2期的に塞栓術を施行した．術後，3カ月後の腹部 MRI では nidus の開存は認めず，右腎の大部分の血流は保たれていた．顕微鏡的血尿も消失した．

（泌尿紀要 **53**：307-310，2007）

* 現：岐阜総合医療センター泌尿器科