

CAVERNOUS HEMANGIOMA OF THE TESTIS A CASE REPORT AND REVIEW OF THE LITERATURE

Ei-ichiro TAKAOKA, Kazumi YAMAGUCHI and Takashi TOMINAGA
The Department of Urology, Mitsui Memorial Hospital

A 73-year-old man consulted our hospital with a painless intra-scrotal mass in the left testis. Serum levels of human beta-chorionic gonadotropin and alpha-fetoprotein were normal. Scrotal ultrasonography demonstrated left testis with a heterogeneous texture. A diagnosis of probable testicular malignancy was made, and a left radical orchiectomy was performed. The histopathological diagnosis was testicular cavernous hemangioma. To our knowledge, only 19 cases of cavernous hemangioma of the testis have been reported in the literature so far. Although this is a rare tumor, it should be considered in the differential diagnosis of testicular tumor.

(Hinyokika Kiyo 53 : 405–407, 2007)

Key words : Cavernous hemangioma, Testis

INTRODUCTION

Benign tumors account for only a small percentage of all testicular tumors, and among them, cavernous hemangioma is extremely rare. Only 19 cases have been previously reported¹⁻⁹⁾. We present a case of cavernous hemangioma and review the literature.

CASE REPORT

A 73-year-old man consulted our hospital with a painless intra-scrotal mass in the left testis of seven months' duration. There was no history of orchitis, trauma, mumps, or inguinoscrotal surgery. Physical examination revealed a slightly indurated and mildly enlarged left testis. The right testis was normal. Serum levels of human beta-chorionic gonadotropin and alpha-fetoprotein were normal. Scrotal ultrasonography demonstrated left testis with a heterogeneous texture. There were hypoechoic areas measuring 13 mm in diameter and regions of calcific shadowing (Fig. 1). Color and power doppler ultrasonography were not

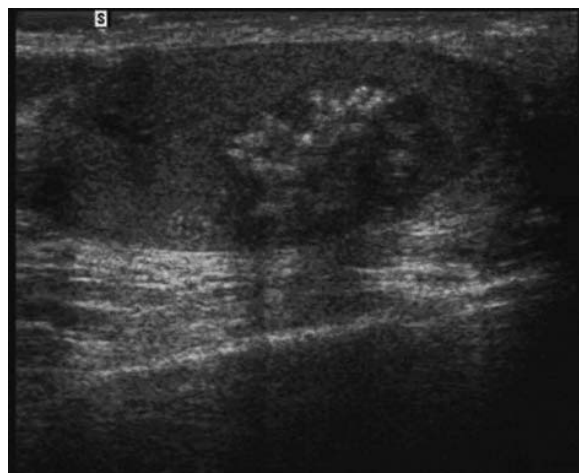


Fig. 1. Longitudinal view by scrotal ultrasonography demonstrating a hypoechoic mass with calcific shadowing.

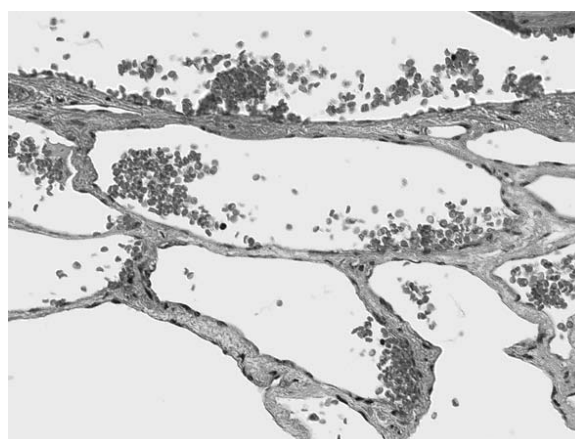


Fig. 2. On gross examination, the tumor was hemorrhagic with calcifications. On microscopic examination, it consisted of dilated spaces filled with red blood cells and lined by flat endothelial cells (H & E stain, $\times 200$). Some areas showed marked fibrosis.

carried out. A diagnosis of probable testicular malignancy was made, and a left radical orchiectomy was performed. On gross examination, the tumor was hemorrhagic with calcifications. On microscopic examination, it consisted of dilated spaces filled with red blood cells and lined by flat endothelial cells (Fig. 2). Some areas showed marked fibrosis. The histopathological diagnosis was testicular cavernous hemangioma.

Postoperative examination that included abdominal and scrotal ultrasonography every three months showed no recurrence of the tumor.

DISCUSSION

Cavernous hemangiomas are benign tumors of vascular origin that can develop in any part of the body. However, its occurrence in the testis is rare. The first reported case of testicular cavernous hemangioma was by Kleiman et al. in 1944, and 19 cases have been reported to date¹⁻⁹⁾. Most subtypes of hemangioma of

the testis have been reported and have been described as cavernous, capillary, histiocytoid, and juvenile, with cavernous hemangioma being the most common²⁾. The patients' ages varied from less than one year to over seventy. The chief presenting symptom was testicular enlargement with or without tenderness³⁾. Some cases were associated with hemorrhagic infarction³⁻⁵⁾. In the histological section, numerous dilated blood sinuses lined by endothelial cells are found¹⁻⁹⁾. Some reports presented the ultrasonographic findings of this tumor: a heterogeneous texture, similar to that of germ cell tumors^{5,6,8,9)}.

There were no case reports of color or power doppler ultrasonographic findings of cavernous hemangioma of the testis. On the other hand, Perkins et al. evaluated the color and doppler sonographic findings of 25 hepatic cavernous hemangiomas to compare them with malignant neoplasm of the liver. In 23 lesions, there was no internal blood flow, and 11 showed a peripheral blood flow pattern believed to represent flow in displaced blood vessels. They concluded that these findings overlap with the appearance of malignant neoplasm, and neither color nor power doppler imaging improved the capability of sonography to make a specific diagnosis of hepatic cavernous hemangioma¹⁰⁾. Geenen et al. reported that power doppler sonography of renal cavernous hemangiomas revealed normal a renal vascular pattern, and they also indicated the difficulty of preoperative diagnosis of this tumor¹¹⁾. It may be difficult to distinguish this tumor from testicular carcinoma using only these modalities preoperatively.

In conclusion, cavernous hemangioma of the testis is a rare entity. At present, it is not feasible to preoperatively distinguish this tumor from the more common testicular tumors (i.e., germ cell, sex corded, stromal). In diagnosing a testicular mass in a patient presenting with normal human beta-chorionic gonadotropin and alpha-fetoprotein values and with an ultrasound study showing a heterogeneous mass, this neoplasm, although rare, should be considered in the differential diagnosis.

REFERENCES

- 1) Kleiman AH: Hemangioma of the testis. *J Urol* **51**: 548-550, 1944
- 2) Suriawinata A, Talerman A, Vapnek JM, et al.: Hemangioma of the testis: report of unusual occurrences of cavernous hemangioma in a fetus and capillary hemangioma in an older man. *Ann Diagn Pathol* **5**: 80-83, 2001
- 3) Fossum BD, Woods JC and Blight EM: Cavernous hemangioma of testis causing acute testicular infarction. *Urology* **18**: 277-278, 1981
- 4) Gharpure KJ, Ahmed YB and Bhargava MK: Cavernous hemangioma of testis with acute testicular infarction—a case report. *Indian J Cancer* **22**: 73-75, 1985
- 5) Lozano V, Alonso P and Marcos-Robles J: Case report: sonographic appearance of cavernous haemangioma of the testis. *Clin Radiol* **49**: 284-285, 1994
- 6) Frank RG, Lowry P and Ongcapin EH: Venous cavernous hemangioma of the testis. *Urology* **52**: 709-710, 1998
- 7) Ogawa O, Yoshimura N, Nishimura K, et al.: A case of cavernous hemangioma of testis. *Acta Urol Jpn* **31**: 2060-2064, 1985
- 8) Tada M, Takemura S, Takimoto Y, et al.: A case of cavernous hemangioma of testis. *Acta Urol Jpn* **35**: 1969-1971, 1989
- 9) Erdag G, Kwon EO, Lizza EF, et al.: Cavernous hemangioma of tunica albuginea testis manifesting as testicular pain. *Urology* **68**: 673.e13-673.e15, 2006
- 10) Perkins AB, Imam K and Smith WJ: Color and power doppler sonography of liver hemangiomas: a dream unfulfilled? *J Clin Ultrasound* **28**: 159-165, 2000
- 11) Geenen RWF, Bakker MA and Bangma CH: Sonography, CT, and MRI of giant cavernous hemangioma of the kidney: correlation with pathologic findings. *Am J Roentgenography* **182**: 411-414, 2004

(Received on September 19, 2006)
(Accepted on January 11, 2007)

和文抄録

精巣海綿状血管腫の1例

高岡栄一郎, 山口 千美, 富永 登志

三井記念病院泌尿器科

73歳, 男性, 左陰囊の無痛性腫大を自覚し来院. 血清 β HCG, AFP は正常であった.

超音波所見では内部エコーの不均一な腫瘍を認めた. 左精巣腫瘍を疑い, 左高位精巣摘除術を施行した. 病理組織学的所見は精巣海綿状血管腫であった. 精巣

海綿状血管腫はこれまで19例の症例報告があるにとどまるが, 精巣腫瘍の鑑別診断として考慮に入れるべき疾患である.

(泌尿紀要 53 : 405-407, 2007)