

BMJ Case Reports

Submission template for full cases

- All case reports MUST be submitted online <http://mc.manuscriptcentral.com/bmjcasereports> using this Word template
 - You will be asked for more detailed information on submission where you can also upload images, tables, multimedia files, etc
 - More information is available in the Instructions for authors <http://casereports.bmj.com/instructions-for-authors>
- You must have **signed informed consent** from patients (or relatives/guardians) before submitting to BMJ Case Reports. Please anonymise the patient's details as much as possible, eg, specific ages, occupations. Blank consent forms are available online <http://casereports.bmj.com/instructions-for-authors/consentform.pdf>
- Individuals pay an annual fellowship fee of £95; US\$180; €130. During your 12 month Fellowship period you can submit as many cases as you like, access all the published material, and re-use any published material for personal use and teaching without further permission.
- Institutional Fellowships are also available
- For more information visit <http://casereports.bmj.com/misc/becomeafellow.dtl>

TITLE OF CASE
Voriconazole-induced periostitis in a patient with overlap syndromes
AUTHORS OF CASE <i>Please indicate corresponding author by *(after the author's name)</i>
Keisho Hirota, Akihiro Yasoda *, Toshihito Fujii and Nobuya Inagaki
SUMMARY <i>Up to 150 words summarising the case presentation and outcome</i>
52-year-old woman with overlap syndrome and interstitial pneumonia underwent immunosuppressive therapy and she was suspected to suffer from pulmonary aspergillosis. Oral voriconazole was initiated, and rapid elevations of ALP were appeared after 4 weeks. After 2 months, the patient presented diffuse pain in bilateral skeletal regions and bone scintigraphy revealed bilateral multiple areas of increased radiotracer uptake. We suspected the skeletal involvement as voriconazole-induced periostitis. Actually, the plasma fluoride level was increased. Voriconazole was replaced to itraconazole, and after 3 weeks, the patient stopped complaining of bone pain concomitant with the decrease in ALP. Voriconazole-induced periostitis is a rare condition but had previously been reported in solid organ or bone marrow transplant patients who received long-term voriconazole therapy. Our present case is distinctive for previous ones, because it was occurred in a patient with connective tissue disease and further with its rapid progression.
BACKGROUND <i>Why you think this case is important – why you decided to write it up</i>
Voriconazole is a triazole agent that contains 3 fluoride atoms ¹ . Although voriconazole is efficacious for the treatment of invasive aspergillosis and recommended by most international guidelines ^{2 3 4} , it is recently reported to cause fluorosis that develops diffuse painful periostitis ^{5 6 7 8 9 10 11 12} . Here we report a case of voriconazole-induced periostitis in a patient with undifferentiated rheumatic diseases, or overlap syndrome. Voriconazole-induced periostitis was previously reported in solid organ or bone marrow transplant patients who received long-term voriconazole therapy. Recently, Gladue et al. reported a case of voriconazole-induced periostitis occurred in a patient with granulomatosis with polyangiitis ¹³ . Our present report would be the

next case of voriconazole-induced periostitis occurred in the course of connective tissue disease. Furthermore, our patient presented the earliest onset of the findings, to our best knowledge.

CASE PRESENTATION *Presenting features, medical/social/family history*

The case is a 52-year-old woman with a history of overlap syndrome, including systemic lupus erythematosus, systemic sclerosis, and dermatomyositis and interstitial pneumonia. She underwent immunosuppressive therapy including cyclosporine and betamethasone. She was admitted to our hospital for exacerbation of interstitial pneumonia and treated with cyclophosphamide pulse therapy. In the course of the treatment, CT scan of the chest showed a cavity in upper-right lung. Although aspergillus antigen and β -D-glucan tests were negative, clinical history and imaging findings were compatible with pulmonary aspergillosis. Oral voriconazole was initiated at the dose of 600 mg/day and persisted to maintain serum levels at about 3 μ g/mL. Approximately after 4 weeks of the initiation of the voriconazole therapy, rapid elevations of ALP were appeared. After the 2-month therapy, the patient presented diffuse pain in bilateral shoulders, humeri, scapulae, and hypochondriac and femoral regions. After 4 months of the initiation of the therapy, bone scintigraphy was performed and revealed multiple areas of increased radiotracer uptake in bilateral scapulae, ribs, and cortex of femurs (figure 1). The bone metabolic markers were elevated; ALP, bone alkaline phosphatase (BAP), tartrate-resistant acid phosphatase (TRACP)-5b and pyridinoline cross-linked carboxyterminal telopeptide of type 1 collagen (1CTP) were 1060 IU/L (normal 115-359 IU/L), 89.3 μ g/L (normal 3.8-22.6 μ g/L), 857 mU/dL (120-420 mU/dL), and 14.0 ng/mL (normal < 5.5 ng/mL), respectively, but serum levels of calcium (9.4 mg/dL adjusted by serum albumin levels, normal 8.7-10.1 mg/dL) and phosphorus (3.5 mg/dL, normal 2.6-4.5 mg/dL), intact PTH (46 pg/mL, normal 10-65 pg/mL), PTHrP (< 1.1 pmol/L, within normal range), and 1,25-dehydroxy vitamin D3 (20-60 pg/mL) were within normal ranges. CT scan revealed periosteal reactions in some sites and exostoses in right scapula and left iliac bone (figure 2). MRI revealed high intensity areas on T2 weighed imaging in cortex of these regions and were compatible with periostitis. Bone biopsy was performed from exostosis of left iliac bone, and the pathological examination revealed increase of bone tissue with osteosclerosis. This was compatible with periostitis but not a specific finding of a distinct disease. Because the symptoms began after the initiation of voriconazole and the pattern of bilateral multiple periosteal involvements is compatible, we suspected the skeletal involvement as voriconazole-induced periostitis. As for the etiology of voriconazole-induced periostitis, fluorosis caused by excess intake of fluorides contained in voriconazole is supposed. So we measured the plasma fluoride level and revealed it to be 24.9 μ mol/L (normal 1-4 μ mol/L, toxic level > 15 μ mol/L).

INVESTIGATIONS *If relevant*

DIFFERENTIAL DIAGNOSIS *If relevant*

TREATMENT *If relevant*

As the fluoride toxicity was suspected, voriconazole was discontinued and itraconazole was started at the dose of 200 mg/day.

OUTCOME AND FOLLOW-UP

After the discontinuance of voriconazole for 3 weeks, the patient stopped complaining of bone pain, and ALP decreased to 458 IU/L. Nevertheless, the plasma fluoride level still remained to be 19.0 μ mol/L.

DISCUSSION *including very brief review of similar published cases (how many similar cases have been published?)*

Prolonged ingestion or inhalation of high levels of fluoride ion causes skeletal fluorosis. Fluoride ion is reported to stimulate osteoblasts and lead to osteosclerosis^{14 15}. Chronic toxicity of fluoride ion contributes to increase the poor-quality bone and painful calcification or ossification of tendon and ligament¹⁶. The chemical and structural characters of fluoride ion resemble those of hydroxide, and the alteration of hydroxyapatite to fluoroapatite induces bone fragility¹⁷.

Voriconazole contains 3 fluoride atoms, which account for 16.3% by weight². As oral bioavailability of fluoride was reported to be 96%, about 78 mg of fluoride was ingested each day in our case. The World Health Organization (WHO) states that there is a clear excess risk of skeletal fluorosis for a total fluoride intake of 14 mg/day and a suggestive evidence of an increased risk of bone effects at total intakes above 6 mg/day¹⁸. Thus, our patient had taken total daily fluoride thirteen times more than the upper limit of the fluoride amount suggested by WHO. In addition, the plasma fluoride level still remained to be 19 μ mol/L 3 weeks after the discontinuance of voriconazole, which is higher than those of general population. Fluoride is excreted in urine or accumulated in bone, and the plasma level of fluoride drops to the value of before intake in 24 hours¹⁹. We think fluoride accumulation in bone caused extended release of fluoride from bone in our case.

Voriconazole-induced periostitis is suspected to be caused by the accumulation of fluoride^{8 9 11}. Patients of voriconazole-induced periostitis develop diffuse pain in extremity and exhibit an elevation of alkaline phosphatase (ALP). These symptoms are reported to appear from 6 weeks to 53 months after the initiation of voriconazole^{5 6 7 8 9 10 11 12}. Radiographic image reveals symmetric periosteal reaction and skeletal lesions consist of periosteal thickening, periosteal calcification, calcification of ligaments, and osteosclerosis predominantly in proximal long bones, ribs, scapulae and iliac bones. Bone scintigraphy exhibits multiple areas of increased radiotracer uptake corresponding to multifocal periosteal lesions^{5 6 7 10 12}. These symptoms are reversible and improve within a few weeks after discontinuation of voriconazole. In past, all cases of voriconazole-induced periostitis were reported to be occurred in transplant recipients^{5 6 7 8 12} or patients with hematological disorders^{9 11}. Recently, Gladue et al. reported a case of voriconazole-induced periostitis occurred in a patient with granulomatosis with polyangitis¹³. Our present report would be the next case of voriconazole-induced periostitis occurred in the course of connective tissue disease. Furthermore, in our case, the elevation of ALP occurred 4 weeks after the initiation of voriconazole and the diffuse pain developed within 2 months. This is the earliest onset of the findings that have ever been reported. Drug-drug interactions or inflammatory processes on periosteum might be the pathogenesis of this condition¹¹.

In conclusion, we reported a case of voriconazole-induced periostitis developed in a patient with connective tissue disease. As the skeletal symptoms are reversible and ameliorated after the discontinuance of voriconazole, physicians should be aware of it when patients taking voriconazole suffer diffuse bone pains.

LEARNING POINTS/TAKE HOME MESSAGES *3 to 5 bullet points*

We must suspect voriconazole-induced periostitis for diffuse bone pain and increased ALP in a patient who is taking voriconazole.

Voriconazole-induced periostitis is a reversible condition and the discontinuance of voriconazole ameliorates the symptoms.

Voriconazole-induced periostitis can occur in patients suffering from collagen diseases.

REFERENCES *Vancouver style (Was the patient involved in a clinical trial? Please reference related articles)*

1. Park BK, Kitteringham NR, O'Neill PM. Metabolism of fluorine-containing drugs. *Annu Rev Pharmacol Toxicol* 2001;41:443-70.
2. Walsh TJ, Anaissie EJ, Denning DW, et al. Treatment of aspergillosis: clinical practice guidelines of the Infectious Diseases Society of America. *Clin Infect Dis* 2008;46(3):327-60.
3. Cornely OA, Bassetti M, Calandra T, et al. ESCMID guideline for the diagnosis

- and management of Candida diseases 2012: non-neutropenic adult patients. *Clin Microbiol Infect* 2012;18 Suppl 7:19-37.
4. Ullmann AJ, Cornely OA, Donnelly JP, et al. ESCMID guideline for the diagnosis and management of Candida diseases 2012: developing European guidelines in clinical microbiology and infectious diseases. *Clin Microbiol Infect* 2012;18 Suppl 7:1-8.
 5. Wang TF, Wang T, Altman R, et al. Periostitis secondary to prolonged voriconazole therapy in lung transplant recipients. *Am J Transplant* 2009;9(12):2845-50.
 6. Wise SM, Wilson MA. A case of periostitis secondary to voriconazole therapy in a heart transplant recipient. *Clin Nucl Med* 2011;36(3):242-4.
 7. Chen L, Mulligan ME. Medication-induced periostitis in lung transplant patients: periostitis deformans revisited. *Skeletal Radiol* 2011;40(2):143-8.
 8. Wermers RA, Cooper K, Razonable RR, et al. Fluoride excess and periostitis in transplant patients receiving long-term voriconazole therapy. *Clin Infect Dis* 2011;52(5):604-11.
 9. Skiles JL, Imel EA, Christenson JC, et al. Fluorosis because of prolonged voriconazole therapy in a teenager with acute myelogenous leukemia. *J Clin Oncol* 2011;29(32):e779-82.
 10. Rossier C, Dunet V, Tissot F, et al. Voriconazole-induced periostitis. *Eur J Nucl Med Mol Imaging* 2012;39(2):375-6.
 11. Gerber B, Guggenberger R, Fasler D, et al. Reversible skeletal disease and high fluoride serum levels in hematologic patients receiving voriconazole. *Blood* 2012;120(12):2390-4.
 12. Becce F, Malghem J, Lecouvet FE, et al. Clinical images: voriconazole-induced periostitis deformans. *Arthritis Rheum* 2012;64(10):3490.
 13. Gladue HS, Fox DA. Voriconazole-induced periostitis causing arthralgias mimicking a flare of granulomatosis with polyangiitis. *J Clin Rheumatol* 2013;19(8):444-5.
 14. Wergedal JE, Lau KH, Baylink DJ. Fluoride and bovine bone extract influence cell proliferation and phosphatase activities in human bone cell cultures. *Clin Orthop Relat Res* 1988(233):274-82.
 15. Takada J, Baylink DJ, Lau KH. Pretreatment with low doses of norethindrone potentiates the osteogenic effects of fluoride on human osteosarcoma cells. *J Bone Miner Res* 1995;10(10):1512-22.
 16. Krishnamachari KA. Skeletal fluorosis in humans: a review of recent progress in the understanding of the disease. *Prog Food Nutr Sci* 1986;10(3-4):279-314.
 17. Riggs BL, Hodgson SF, O'Fallon WM, et al. Effect of fluoride treatment on the fracture rate in postmenopausal women with osteoporosis. *N Engl J Med* 1990;322(12):802-9.
 18. Environmental Health Criteria 227: FLUORIDE. World Health Organization; 2002; Geneva.
 19. Itai K, Onoda T, Nohara M, et al. Serum ionic fluoride concentrations are related to renal function and menopause status but not to age in a Japanese general population. *Clin Chim Acta* 2010;411(3-4):263-6.

Figure captions

figure 1

Bone scintigraphy representing multiple areas of increased radiotracer uptake in bilateral scapulae, ribs, and cortex of femurs after 4 months of the initiation of voriconazole.

figure 2
CT images showing exostoses in right scapula and left iliac bone (red arrows).

Copyright Statement

I, *Akihiro Yasoda*, The Corresponding Author, has the right to assign on behalf of all authors and does assign on behalf of all authors, a full assignment of all intellectual property rights for all content within the submitted case report (other than as agreed with the BMJ Publishing Group Ltd) ("BMJ Group") in any media known now or created in the future, and permits this case report (if accepted) to be published on BMJ Case Reports and to be fully exploited within the remit of the assignment as set out in the assignment which has been read. (<http://casereports.bmj.com/instructions-for-authors/copyright.pdf>)."

Date:
2013.12.25

PLEASE SAVE YOUR TEMPLATE WITH THE FOLLOWING FORMAT:

Corresponding author's last name and date of submission, eg,

Smith_May_2009.doc

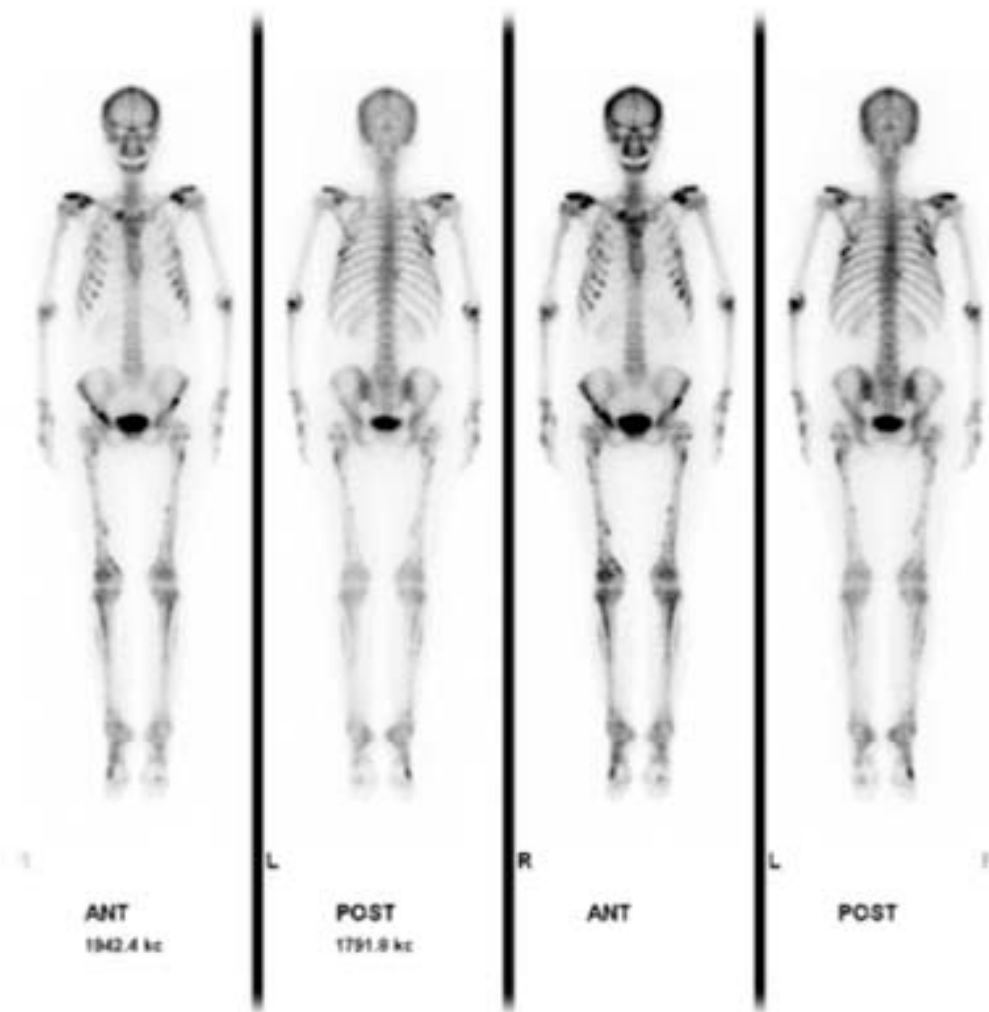


figure 1

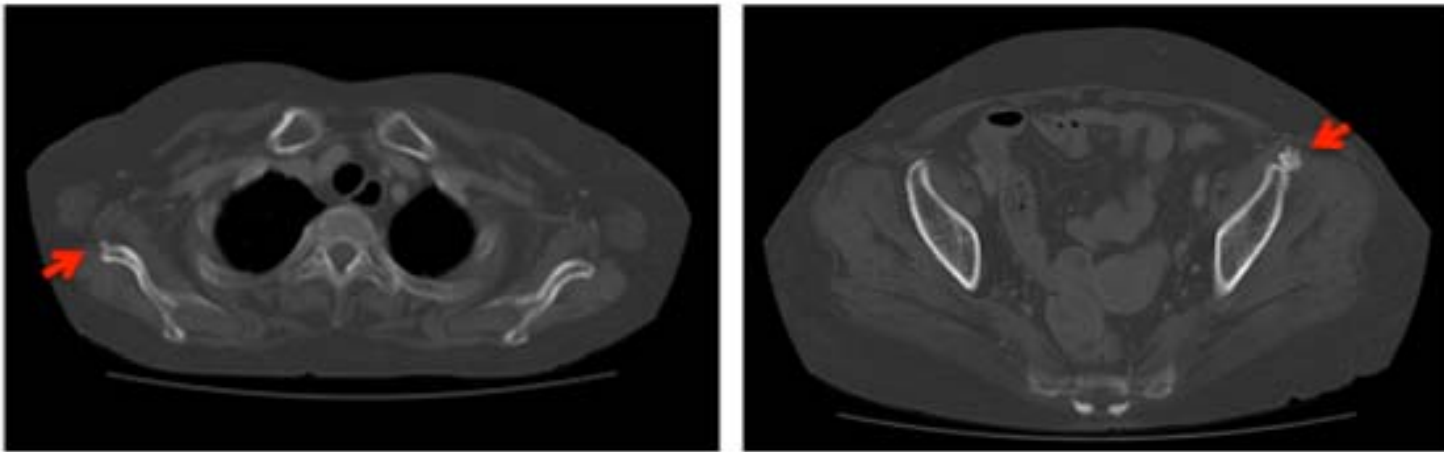


figure 2