原　　著

Fluorescence Histochemical Studies on the Distribution of Adrenergic Nerve Fibers to Intracranial Blood Vessels

by

HIROSHI KAJIKAWA

Department of Neurosurgery, School of Medicine, Kyoto University
(Director : Prof. Dr. HAJIME HANDA)

Department of Pharmacology, School of Medicine, Kyoto University
(Director : Prof. Dr. KIRO SHIMAMOTO)

Received for Publication May. 6, 1968

Although the sympathetic innervation of the cerebral vessels has been settled, there is no evidence to show that it is physiologically active. However, the cerebral circulation is very unique in exhibiting the autoregulation mainly by changing the vascular resistance [19)27)]. In this respect, the morphological details of the adrenergic innervation of the respective cerebral vessels as well as the differential contributions of the postganglionic fibers from the cervical and thoracal sympathetic ganglions has not yet been elucidated.

The highly specific fluorescent technique for the histochemical detection of the endogenous noradrenaline introduced by FALCK[8)] is available for the observation of the adrenergic innervation of the cerebral vessels In the present experiments attempts have been made to know the topographic and histological modes of distribution of the adrenergic nerve fibers in the cerebral arteries of the rats, guinea-pigs and cats.

METHODS

Rats of Wistar strain weighing 200 to 250 g, guinea pigs weighing 300 to 350 g, and cats (Kitten) weighing 300 to 400 g were used. The animals were sacrified by decapitation for removing of the whole head. By exposing the whole brain with the attaching carotid and vertebral arteries the brain tissue was sectioned coronally into 6 or 7 pieces at the thickness of 3 mm from the frontal tip to the medulla oblongata.

Some of the rats and guinea-pigs were previously subjected to the bilateral or unilateral superior cervical and stellate ganglionectomies under pentobarbital anesthesia. Twenty-four hours to 180 days after the surgical procedure the animals were similarly sacrified for removing of the head. Some other animals were subjected to the surgical decentralization of the unilateral superior carvical ganglion also for sectioning of the brain tissue.

The brain tissue and the cerebral vessels were examined histochemically following

the modification[13] of the original fluorescent method of FALCK[8]. Pieces of the brain sections frozen in isopentane cooled at −100°C with liquid nitrogen were dehydrated in vacuo at a temperature of −30° to −35°C for 5 to 7 days The fully dehydrated tissue sections were exposed to formaldehyde gas at 80°C for one hour in a glass jar containing paraformaldehyde. Then, the tissue sections were infiltrated in vacuo with paraffin at 60°C for 30 minutes. The paraffinized tissue sectioned at the thickness of 8 μ was placed on the non-fluorescent slide glass and was mounted with a mixture of Entellan (Merck) and xylene in the same ratio. The adjacent two tissue sections were stained with hematoxylin-eosin and PAS for the confirmation of the tissue structures.

The fluorescent sections were observed and photographed on the Kodak Tri-X film by use of the fluorescent microscope (Carl-Zeiss). The exciting light was delivered from an Osram high pressure mercury lamp and was filtered through Schott BG 12 and Zeiss 50 as the primary and secondary filters. Exposure time ranged from 90 to 120 seconds. The specifity of the fluorescence was confirmed with the quenching of the fluorescence by exposing the fluorescent tissue to sodium borohydride[5].

RESULTS

I. Normal distribution of the adrenergic nerve fibers to the cerebral vessels

The extracranial portions of the internal carotid artery in rats, guinea-pigs and cats exhibited the abundant presence of the noradrenaline fluorescent nerve fibers. In the cross sections of the artery and its branches the yellowish-green fluorescenct fibers with the varicose structures were found in the adventitial layers encircling the vessels The longitudinal sections of the artery showed the extension of the same fluorescent fibers toward the periphery of the artery. Many fluorescent fiber branches were also found in their course. Some of the branch fibers were found in the close proximity of the external surface of the media. The intence green fluorescence found in the internal elastic lamina and the elastic fibers of the media proved to be non-specific. The distribution of the specific fluorescent fibers varied somewhat according to the diameter of the artery and its branches, and the small-sized arteries showed a relatively rich distribution. On the other hand, the juglar veins exhibited almost no specific fluorescence. No significant difference in the pattern of the distribution of the specific fluorescence was observed among rats, guinea-pigs and cats.

The major arteries at the base of the brain exhibited also the abundant presence of the specific fluorescent fibers with varicose structures only on the outer border of muscle layer and never in the muscle layer proper (Figs. 1 and 2). The fluorescent fibers were 0.5 to 2.0 μ in diamter and were usually discontinuous at the distance of 3 to 6 μ in the cross section of the artery. The fluorescent fibers were much more abundantly found in the arteries belonging to the internal carotid system such as the anterior cerebral, middle cerebral, posterior communicating and posterior cerebral arteries than in those belonging to the vertebro-basilar system such as vertebral and basilar arteries. The distributions of the fluorescent fibers tended to reduce with the decrease of the arterial diameter toward the periphery. The specific fluorescent fibers in the external layers were still found in the arterioles showing the diameter of 15 μ or less. However, no specific fluorescence was

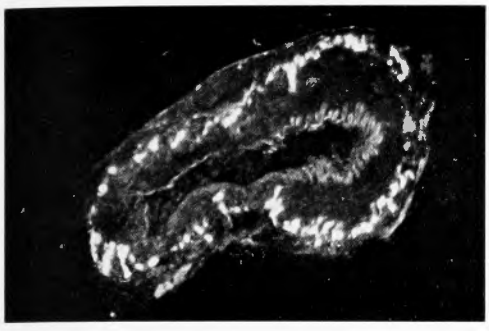

Fig. 1. The intracranial portion of internal carotid artery of rat. The fluorescent adrenergic nerve fibers with varicose structures are located on the outer border of muscle layer. Rarely found nerve fibers in the muscularis of the vessels should be considered as artifacts due to an accidental oblique plane of section of the vessel wall. Fluorescence Microphotograph × 320.

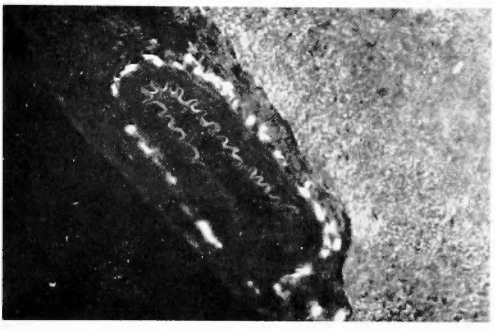

Fig. 2. The middle cerebral artery of rat. ×320

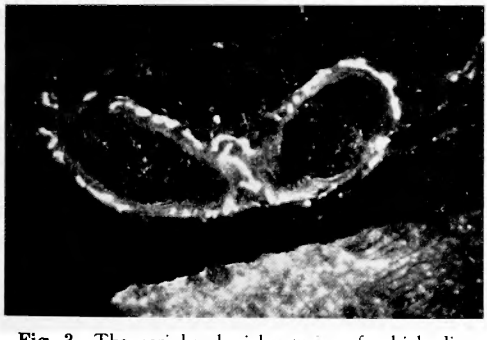

Fig. 3. The peripheral pial arteries of which diameter are about 50 μ (rat). Nerve fibers are seen to connect freely to those of neighboring artery. ×640

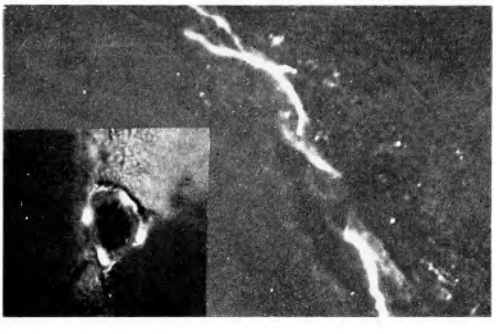

Fig. 4. The intramedullary artery of cat, of which diameter is 25 μ. The adrenergic nerve fibers run in spiral along the artery. (Corner) The artery, 40 μ in diameter, in the basal ganglia of guinea-pig. ×128

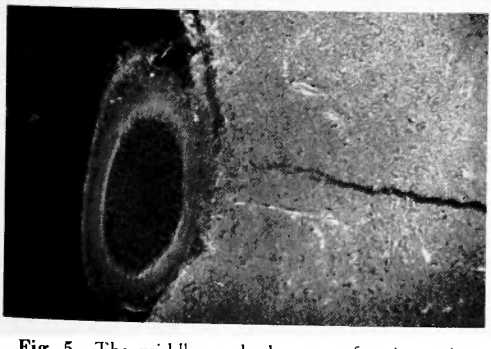

Fig. 5. The middle cerebral artery of guinea pig. Complete disappearance of fluorescence of adrenergic nerve fiber after ipsilateral superior cervical ganglionectomy. ×128

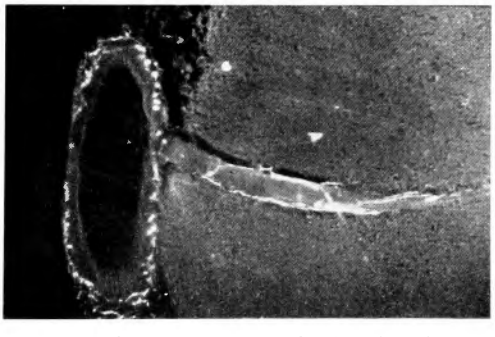

Fig. 6. The same artery on the contralateral control side. Fluorescent adrenergic nerve fibers with varicose structures are intact. And note the adrenergic nerve fibers along with the radiating branch. ×128

observed in the capillaries, venules and veins. Nerve fibers in small arteries were often seen to connect freely to the neighboring artery (Fig. 3). These patterns of the specific fluorescent fibers in distribution did not significantly differ among three pieces used.

The intracerebral arteries exhibited also the specific fluorescent fibers mainly in the external layer. The specific fluorescent fibers of the intracerebral arteries were usually far less dense in distribution than those of the pial arteries in guinea-pig and cat, though the distribution was almost similar in pattern. Especially in rat, the specific fluorescent fibers along with the intracerebral artery was extremely rare. The fluorescent fibers along with the intracerebral arteries was a direct continuation of those in the pial artery. Besides, the longitudinal section of the intracerebral artery showed a continuous distribution of the fluorescent fibers along the artery (Figs. 4 and 6). No significant difference in the arterial distribution of the specific fluorescent fibers was observed according to the topographic sites of the brain structures. In contrast to the distribution of the specific fibers in the arterioles in the brain, the veins, venules and capillaries did not show the specific fluorescence. However, the subependymal capillaries of the choroid plexus exhibited the yellowish-green fluorescence of noradrenaline in some cases.

II. Effects of sympathetic denervation and decentralization

As shown in Table 1, the uni- or bilateral stellate ganglionectomy resulted in the complete disappearance of the specific fluorescence in the adrenergic nerve fibers of the vertebral and basilar arteries but not in those of the anterior cerebral, middle cerebral and posterior communicating arteries. On the other hand, the uni- or bilateral superior cervical ganglionectomy produced the complete disappearance of the specific fluorescence in the adrenergic nerve fibers of the middle cerebral and posterior communicating arteries without affecting the specific fluorescence in the vertebral and basilar arteries. Moreover, either ganglionectomy produced a marked reduction of the specific fluorescence in the posterior cerebral artery of many of the rats. The disappearance of the specific fluorescence caused by ganglionectomy began to develop from 24 hours and was completed at 5 days, as described below.

Though the disappearance of the specific fluorescence in the basilar and vertebral

Table 1. Density of fluorescent adrenergic nerve fibers after the cervical ganglionectomy in rat

	Stellate Ganglionectomy					Superior Cervical Ganglionectomy						
	Bilateral			Unilateral		Bilateral				Unilateral		
vertebral art.	−	−	−	−	−	+	+	+	−	+	+	+
basilar art.	−	−	−	↓	↓	+	+	+	↓	+	+	+
middle cereb. art.	+	+	+	+	+	−	−	−	−	−	−	−
anterior cereb. art.	+	+	+	+	+	−	−	−	−	↓	↓	↓
posterior comm. art.	+	+	+	+	+	−	−	−	−	−	−	−
posterior cereb. art.	+	↓	↓↓	+	↓	−	+	↓↓	−	−	+	↓↓
internal carotid art.	+	+	+	+	+	−	−	−	−	−	−	−
No. of animals	1	2	1	7	2	3	1	5	1	4	1	8
Total	4			9		10				13		

Symbols ; + = unchanged, − = eliminated, ↓ = slightly reduced, ↓↓ = marked reduced.

Table 2. Time-course of reduction or disappearance of fluorescence in the middle cerebral artery after the ipsilateral superior cervical ganglionectomy (in rat and guinea-pig)

	Rat		Guinea-pig	
	Ganglionectomy	Decentralization	Ganglionectomy	Decentralization
24 hrs	+++++	+++++	+++++	+++++
36 〃	++↓−−	+++++	+++↓−	+++++
2 days	++↓↓−−	+++++	++↓−−	+++++
3 〃	+↓−−−	+++++	++↓−−	+++++
5 〃	↓−−−−	+++++	↓↓−−−−	+++++
7–14 〃	−−−−−	+++++	−−−−−	+++++
30 〃	−−−−−	+−+++	−−−−−	+↓↓++
90 〃	−−−−−	+↓↓++	−−−−−	+++++
180 〃	−−−−−	+++++	−−−−−	+++++
No. of animals	45	45	45	45

arteries caused by the bilateral stellate ganglionectomy was complete, the unilateral stellate ganglionectomy produced the complete disappearance in the ipsilateral vertebral artery but the incomplete disappearance in the basilar artery. As mentioned above, even either bilateral or unilateral ganglionectomy failed usually to produce the complete disappearance of the specific fluorescence in the posterior cerebral artery but produced a marked reduction of the specific fluorescence.

The effects of the unilateral superior cervical ganglionectomy or its decentralization on the specific fluorescence of the adrenergic nerve fibers in the ipsilateral middle cerebral artery of the rats and guinea-pigs were persuited from 24 hours to 180 days after surgical operation. The results are shown in Table 2. The sympathetic decentralization produced no significant changes of the specific fluorescence. The specific fluorescence in the artery disappeared completely from 5 days after the surgical ganglionectomy (Figs. 5 and 6). No reappearance of the fluorescence was attained within 180 days after the operation.

The unilateral superior cervical ganglionectomy affected variably the specific fluorescence of the adrenergic nerve fibers in the posterior cerebral artery from 7 days after the operation according to the individual animals, as shown in Fig. 7. Twelve of 53 animals showed the complete disappearance and 36 of 53 animals showed a marked reduction of the fluorescence. Other five animals were not affected or showed a slight reduction of the

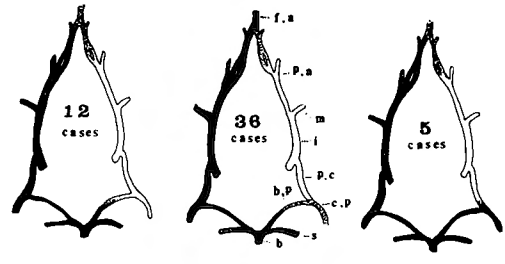

Fig. 7. The distribution of adrenergic nerve fibers originating from the ipsilateral superior cervical ganglion to the arterial circle of Willis. Noradrenaline fluorescence of adrenergic nerve fibers: no visible change (black), reduction (dotted) and disappearance (white) after the ganglionectomy. Abbreviations; f. a. (fused anterior cerebral artery), p. a. (proximal part of anterior cerebral artery), m. (middle cerebral artery), i. (internal carotid artery), p. c. (posterior communicating artery), c. p. (carotid part of posterior cerebral artery), b. p. (basilar part of posterior cerebral artery), s (superior cerebellar artery), b. (basilar artery). Model of Willis ring from Brown's illustration.

fluorescence. In these respects, guinea-pig did not behave differently from the rats.

In the circle of Willis there is formed an arterial ring, into which there enters on each side the posterior cerebral, posterior communicating, internal carotid, anterior cerebral and anterior communicating arteries. The unilateral superior cervical ganglionectomy produced the total disapperance of the specific fluorescence in the internal carotid, middle cerebral, proximal anterior cerebral and posterior communicating arteries. The specific fluorescence in the anterior cerebral artery distal to the convergence of the anterior communicating artery was comcletely disappered by the bilateral superior cervical ganglionectomy but was slightly or considerably reduced by the unilateral ganglionectomy. However, either procedure alone usually failed to produce the complete disappearance of the specific fluorescence in the posterior cerebral artery. This evidence also indicates that some of the adrenergic nerve fibers in the circle of Willis originates from the stellate ganglion probably via the vertebral artery. On the other hand, the specific fluorescence in the vertebral artery was disappeared by the superior cervical ganglionectomy alone in 4 of 33 rats and in 3 of 20 guinea-pigs. These evidences show that the circle of Willis and also the vertebral artery are supplied variably or being overlapped according to the individual animals with the adrenergic fibers originating from the superior cervical or/and stellate ganglion.

DISCUSSION

The free anastomosis of the cerebral arteries at the base of brain including the circle of Willis has been accepted to provide for a collateral circulation when one of the tributary vessels is occluded. Since the first demonstration of the nerve supply to the circle of Willis by PURKINJE and REMAK[23], the mode of the innervation of the cerebral vessels has extensively been studied anatomically and physiologically[3)4)10)12)17)21)23)25]. The researchers were consistent with the sympathetic innervation of the cerebral vessels in the cervico-thoracal origin. Due to the lack of a specific method for the histological demonstration of the adrenergic nerve fibers the questions such as the differential distribution and differential participation of the cervical and thoracal sympathetic systems according to the individual vessels have remained to be settled. In addition, there has been no clear-cut evidence to support the clinical effects that the stellate ganglion block is relieving for the cerebrovascular disorders.

The histochemical fluorescent technique of FALCK[8] was used in the present experiments to demonstrate the adrenergic nerve fibers innervating the cerebral vessels. The intracranial arteries as well as the extracranial portion of the internal carotid artery exhibited the fine fibers of noradrenaline fluorescence with varicose structures only in the external and adventitial layers. Some of the fibers were found in the outer proximity of the media. The fluorescent fibers were confirmed to extend toward the peripheral portion along the arterial wall. These findings were consistent with the similar descriptions by FALCK et al.[9], OHGUSHI[20] and also with the electron microscopical observations[6] of the pial artery.

Though the fluorescent fibers became to be more dense in distribution associated with the reduction in diameter of the extracranial portion of the internal carotid artery and its branches, the same distribution of the fluorescent fibers in the intracranial arteries was

decreased associated with the reduction in diameter. The decreased distribution of the adrenergic nerve fibers toward the periphery of the intracranial artery indicates the relatively minor contribution of the adrenergic mechanism in regulating the cerebral blood flow. The abundant presence of the adrenergic nerve fibers in the cerebral arteries of the present experiments, in contrast to the occassional presence of the nerve fibers by the silver impregnation method[21], seems to show the excellence of the FALCK's method.

There are some differences in distribution of the adrenergic nerve fibers according to the individual arteries. The distribution of the adrenergic nerve fibers was always more marked in the carotid system than in the vertebro-basilar system. This seems to be well consistent with the anatomical findings that the internal carotid nerves derive from the superior cervical ganglion are very rich, but the vertebral nerves from the stellate ganglion are poor[25]. The pial arteries and their branched intracerebral arteries and arterioles presented also the innervation of the adrenergic nerve fibers. The veins, venules and capillaries in the brain did not practically show the presence of the adrenergic nerve. However, the presence of the noradrenaline fluorescence was confirmed in the subependymal capillaries of the choroid plexus in some of the rats, guinea-pigs and cats. The constriction of the capillaries in the choroid plexus by stimulation of the cervical sympathetic nerve[22] as well as the complete degeneration of the vascular nerves in the choroid plexus by the total sympathectomy[24] were also regarded to provide evidence for the innervation of the choroid plexus by the sympathetic nerves. As for the adrenergic mechanism at capillary level, the present author[16] observed that the administration of L-dopa to the rats pretreated with monoamine oxidase inhibitor produced an accumulation of the catecholamine fluorescence in the endothelial epithels of the intracerebral capillaries.

Though the superior cervical sympathetic decentralization did not affect the specific fluorescence in any of the cerebral arteries, the superior cervical or stellate ganglionectomy resulted in the complete disappearance of the specific fluorescence in the cerebral arteries innervated by the adrenergic fibers from the respective ganglion. In the present experiments, the disappearance of the noradrenaline fluorescence in the arterial wall after the ganglionectomy was completed within 5 days. Much earlier disappearance of fluorescence than the structural changes[4][24] after the removal of superior cervical ganglion seems to indicate that functional failure of adrenergic nerve fibers to take up and store noradrenaline precede with the morphological changes. DAHLSTRÖM[7] has postulated that the noradrenaline in the adrenergic nerve fibers in the tissues derives from the downward transfer from the noradrenaline-containing cells in the sympathethic ganglion and the time-length required for the total disappearance of the specific fluorescence after the ganglionectomy relates with the downward velocity of the amine. The relatively early depletion of the iris noradrenaline after the superior cervical ganglionectomy[1] seems to show that the transfer velocity of the amine differs considerably according to the individual nerves. When the noradrenaline fluorescence in the cerebral arteries was lost completely after the surgical ganglionectomy, no recurrence of the fluorescence was attained within 6 months.

The topographic status of the circle of Willis in the mammalian species is essentially similar except in the rats, which has a fused anterior cerebral artery and a relatively large posterior communicating artery. In addition, BROWN[2] has desribed several variations of the circle of Willis in rats. In the present experiments the differential innervation of the

cerebral arteries including the circle of Willis by the superior cervical or stellate ganglion were confirmed by the disappearance of the noradrenaline fluorescence after the respective ganglionectomy. The unilateral superior cervical ganglionectomy resulted in the complete disappearance of the specific fluorescence in the internal carotid, middle cerebral and posterior communicating arteries and also in the proximal portion of anterior cerebral artery. The same surgical procedure produced usually a marked reduction of the fluorescence but not a disappearance in the posterior cerebral artery on the ipsilateral side. The bilateral superior cervical ganglionectomy produced the bilateral disappearance or reduction of the fluorescence in the posterior cerebral artery. However, the complete disappearance of the specific fluorescence in the distal portion of the anterior cerebral artery by the bilateral superior cervical ganglionectomy but not by the unilateral one alone indicated the overwhelmingly overlapping innervation by the adrenergic nerve fibers from the bilateral ganglions.

It is known that the posterior cerebral artery originates embryologically from the internal carotid artery. WILLIAMS[26] has shown that the nerve fibers innervating the posterior cerebral artery in the human are the direct continuation of the nerve fibers innervating the internal carotid artery via the posterior communicating artery. However, MCNAUGHTON[18] has shown in ape that the nerve fibers innervating the posterior cerebral artery come from the basilar artery. In the present experiments the superior cervical ganglionectomy either unilaterally or bilaterally did not affect the specific fluorescence in the vertebral and basilar arteries. The specific fluorescence in these arteries disappeared completely by the bilateral stellate ganglionectomy and to a lesser degree by the unilateral one.

As mentioned above, the superior cervical ganglionectomy produced the complete disappearance of the specific fluorescence in the posterior cerebral artery in 12 of 53 animals (rats and guinea-pigs) and a marked reduction of the same fluorescence in 36 of 53 animals. Since the stellate ganglionectomy alone reduces also considerably the specific fluorescence in the posterior cerebral artery, the adrenergic nerve fibers are concluded to be supplied from both the superior cervical and stellate ganglions. The disappearance of the specific fluorescence in the ipsilateral vertebral artery in 7 of 53 animals received previously the unilateral superior cervical ganglionectomy indicates that some of the adrenergic fibers from the superior cervical ganglion innervate the vertebral artery. Although FOLEY[11] has suggested that the cells of the superior cervical ganglion project axons inferiorly in the trunk and innervate the vertebral artery, the sequence is not proved in the present experiments. The results described above show that the clinical effects of the stellate ganglionectomy, if any, provide the sympathetic denervation and/or decentralization effect only for the vascular disorders of the vertebral and basilar artery, and provide the sympathetic decentralization effect for those of the internal carotid syetem.

SUMMARY

Using a histochemical fluorescence method of FALCK, the distribution of adrenergic nerve fibers to the intracranial blood vessels has been studied in rats, guinea-pigs and cats.

1. Adrenergic nerve fibers were seen in the pial and intracerebral blood vessels as small as 15 μ in diameter. However, veins, venules and capillaries did not practically show the presence of the adrenergic nerves.

2. Though the adrenergic nerve fibers were more dense in distribution associated with the reduction in diameter of the extracranial portion of the internal carotid artery and its branches, the same distribution of the fluorescent fibers in the intracranial arteries decreased associated with the reduction in diameter.

3. The disappearance of the specific fluorescence of adrenergic nerve fiber caused by the surgical ganglionectomy began to develop from 24 to 36 hours and was completed at 5 days, and no recurrence of the fluorescence was attained 6 months. However, the sympathetic decentralization produced no significant change of fluorescence in any of the cerebral arteries.

4. Adrenergic nerve fibers innervating the proximal part of anterior cerebral, middle cerebral, internal carotid and posterior communicating arteries originate from the ipsilateral superior cervical ganglion; the distal part of anterior cerebral artery is overlappingly innervated by the adrenergic nerve fibers from the bilateral superior cervical ganglions. The vertebral and basilar arteries were innervated by the stellate ganglions. The superior cervical ganglionectomy produced the complete disappearance of the specific fluorescence in the posterior cerebral artery in 12 of 53 animals and a marked reduction of the same fluorescence in 36 of 53 animals, but in the remaining five cases no significant change of specific fluorescence. Moreover, in 7 of 53 animals the vertebral artery was innervated by the ipsilateral superior cervical ganglion. This evidence snows that the circle of Willis and also the vertebral artery are supplied variably or being overlapped according to the individual animals with the adrenergic fibers originating from the superior cervical or/and stellate ganglion.

5. The clinical effects of stellate ganglionectomy, if any, seems to provide the sympathetic denervation and/or decentralization effect only for the vascular disorders of the vertebral and basilar arteries and to some extent for those of the posterior cerebral artery, and provide the sympathetic decentralization effect for those of internal carotid system.

ACKNOWLEDGEMENT

My grateful thanks are sent to Dr. T. OHTA, Dept. of Neurosurgery, Kyoto Univ. Med. School, for his continuous advice and encouragement. I am very much indebted to Dr. M. FUJIWARA and Dr. C. TANAKA, Dept. of Pharmacology, Kyoto Univ. Med. School, for their kind guidance. I should also like to thank Mr. T. MURYOBAYASHI for his technical assistance throughout the work, and my best collegue Dr. H. HAEBARA, Dept. of Pathology, Kyoto Univ. Med. School, for teaching the technique of sympathectomy in rat. This work was supported in part by a grant from the Ministry of Education of Japan (UDC 611.81 · 611-42). Preliminary reports of this work were presented at the meeting of Japan Society of Neurovegetative Research, Oct.1967[14] and Japanese College of Angiolog, Nov. 1967[15].

REFERENCES

1) Andén, N-E. : Disappearance of monoamines and of enzymes responsible for their formation after denervation. In "Mechanisms of Release of Biogenic Amines" edited by U. S. von Euler, S. Rosell and B, Uvnäs. Wenner-Gren Center. International Symposium Series. Pergamon Press. vol. **5** : 177-179, 1966.

2) Brown, E. : The morphology of circulus arteriosus cerebri in rat. Anat. Rec. **156** : 99-106, 1966.

3) Carrato-Ibanez, A., and Abadia-Fenoll, F., : Morphology and origin of the perivascular fibers into the brain substance. Angiology. **17** : 771-783, 1966.

4) Chorobski, J., and Penfield, W. : Cerebral vasodilator nerves and their pathway from the medulla oblongata. With observation on pial and intracerebral vascular plexus. Arch. Neurol. Psychiat. **28** : 1257-1287,

1932.
5) Corrodi, H., Hillarp, N-Å., and Jonsson, G. : Fluorescence method for the histochemical demonstrations of monoamines. 3. Sodium borohydride reduction of the fluorescent compounds as a specific test. J. Histochem. Cytochem. **12** : 582-586, 1964.
6) Dahl, E., and Nelson, E. : Electron microscopic observatons on human intracranial arteries. Arch. Neurol. **10** : 158-164, 1964.
7) Dahlström, A., and Häggendal, J. : Studies on the transport and life-span of amine storage granules in a peripheral adrenergic neuron system. Acta Physiol. Scand. **67** : 278-288, 1966.
8) Falck, B. : Observations on the possibilities of the cellular localization of monoamines by a fluorescence method. Acta Physiol. Scand. **56** : suppl. 197. 1-25, 1962.
9) Falck, B., Mchedlishvili, G. I., and Owman, C. : Histochemical demonstration of adrenergic nerves in cortex-pia of rabbit. Acta Pharmacol. et Toxicol. **23** : 133-142, 1965.
10) Fang, H. S. : Cerebral arterial innervations in man. Arch. Neurol. **4** : 651-656, 1961.
11) Foley, J. O. : The component of the cervical sympathetic trunk with special reference to its accessory cells and ganglia. J. Comp. Neurol. **82** : 77-91, 1945.
12) Forbes, H. S. : Cerebral circulation I. Observation and measurement of pial vessels. Arch. Neurol. Psychiat. **19** : 751-761, 1928.
13) Fujiwara, M., Tanaka, C., Honjo, T. and Okegawa, T. : Histochemical demonstration of noradrenaline in rat salivary glands. Jap. J. Pharmacol. **15** : 369-377, 1965.
14) Handa, H., Kajikawa, H., Ohta, T., and Osaka, K.: Sympathetic innervation on intracranial vessels-Preliminary study- (Japanese). Auton. Nerv. Sys. **4** : No. 2. 72-73, 1967.
15) Handa, H., Kajikawa, H., Ohta, T., and Osaka, K., : Sympathetic innervation on intracranial vessels. J. Jap. Coll. Angiol. **8** : 216, 1967.
16) Kajikawa, H. : Monoamine barrier mechanisms in cerebral edema. To be published.
17) Klosovskii, B, N. : Blood circulation in the brain. (transulated from Russian) Jerusalem, Israel, 1963.
18) McNaughton, F. L. : The innervation of the intracranial blood vessels and dural sinus. A. Res. Nerv. Ment. Dis., Proc., **18** : 178-200, 1938.
19) Meyer, J. S., Handa, J., Huber, P., and Yoshida, K. : Effect of hypotension on internal and external carotid flow. Demonstration of a homeostatic mechanism peculiar to cerebral vessels and its importance in cerebrovascular occlusion. J. Neurosurg. **23** : 191-196, 1965.
20) Ohgushi, N. : Adrenergic fibers to the brain and spinal cord vessels in the dog. Arch. Jap. Chir. Bd. 37. Nr. **2**. : 294-302, 1968.
21) Penfield, W. : Intracerebral vascular nerves. Arch. Neurol. Psychiat. **27** : 30-44, 1932.
22) Putnam, T. J., and Ask-Upmark, E. : Cerebral circulation XXIV. Microscopic observations of the living choroid plexus and ependym of the cat. Arch. Neurol. Psychiat. **32** : 72-80, 1934.
23) Stöhr, P. : Mikroscopische Anatomie des vegetativen Nervevsystems. Springer-Verlag, Berlin, 1928.
24) Tsuker, M. : Innervation of the choroid plexus. Arch. Neurol. Psychiat. **58** : 474-483, 1947.
25) White, J. C. : Nervous contrnl of the cerebral vascular system. In "Clinical Neurosurgery" edited by W. M. Mosberg, Baltimore, Wavery press, 1963.
26) Williams, D. J. : The origin of the posterior cerebral artery. Brain. **59** : 175-180, 1936.
27) Yoshida, K., Meyer, J. S., Sakamoto, K., and Handa, J. : Autoregulation of cerebral blood flow. Electromagnetic flow measurements during acute hypertension in the monkey. Circul. Res., **19** : 726-738, 1966.

和文抄録

脳血管の交感神経支配

京都大学脳神経外科学教室（指導：半田　肇教授）

京都大学薬理学教室（指導：島本暉朗教授）

桾　川　　博

脳血管の神経支配については既に19世紀より Purkinje, Remak, Gulland, Huber 等が報告し今世紀に到り Stöhr, Penfield, Busch, Kuntz, Fang 等により，知覚性，副交感性，交感性の3種の神経線維の存在が示唆されている．このうち主なるものは頸部交感神経節を介する交感神経節後線維であることは一般に認められているが染色性が特異的でないため異論が多い．最近になつて Falck, Hillarp 等主として Sweden 学派が biogenic amines（noradrenaline, dopamine, adrenaline 及び serotonine）を細胞レベルで組織化学的にきわめて鋭敏かつ特異的に検出するいわゆる螢光法を見い出した．

著者は，ラッテ，モルモット，猫の脳血管壁の神経線維の追求にこの方法を用い，交感神経節後線維の transmitter である noradrenaline が特異的に緑色および黄緑色の螢光を発しこれらの動物の脳血管壁に分布しているのを見た．

結果：(1)軟脳膜血管については主として脳底部の脳主幹動脈および比較的太い動脈では交感神経線維は横断面で直径0.5～2μで3μ～6μの間隔で比較的規則正しく血管の周囲に特に外膜層（筋層には認められない）に分布し，末梢の細い動脈では不規則な疎な神経線維となる．これに反し頭蓋外の内頸動脈及びその分枝では細い動脈ほど密な神経神維を有する．また内頸動脈系の交感神経線維は椎骨脳底動脈系のそれに比してはるかに密な分布を示す．これらの所見は動物間で差異を認めない．

(2) 脳実質内の動脈は，わずか1～数本の交感神経線維が血管に沿い糸状にあるいは圧曲し，または樹枝状あるいはラセン状に走行するものが多く，螢光も弱く恒常的に検出することは困難である．特にラッテにおいては極めて稀にしか認めることができない．

(3) 軟脳膜および脳実質内の動脈はいずれも外径15μ位までの細動脈まで交感神経線維を追求できる．従来脳実質内の神経支配については異論が多いがこの方法により確かに神経支配があり，しかもかなり細い動脈にまで及んでいることがわかつた．しかし(2)でのべた如き所見からその意義はあくまでも minor であると思われる．

(4) 毛細管には交感神経線維はなく，また静脈系にはかかる明確な神経支配は微弱でしかも極めて稀にしか認めることが出来ない．

脈絡叢は拡散（diffusion）を来し易い組織であるがその間質の毛細血管網（15μ以下）にも交感神経線維を認め得る．

(5) 頸部交感神経節を外科的に摘出すると，その支配血管壁の交感神経線維のノルアドレナリン螢光は早い動物では24～36時間後に既に消失し5日以内に全例消失をみた．かようにして一旦消失した螢光は6ヵ月間の観察期間中には再現しなかつた．これに反し，神経節を残しその中枢の神経索切断（decentralization）では支配血管壁の神経線維の螢光は6ヵ月後でも全然影響をうけず残存する．

(6) ラッテ，モルモットの上頸神経節及び星状神経節を種々の組合せにより切除して各神経節の支配血管域を決定した．内頸動脈，前大脳動脈の中枢部（両側合して一本になる前），中大脳動脈，後交通動脈は同側の上頸神経節支配であり，前大脳動脈の末梢部（fused portion）は両側の上頸神経節由来であつた．椎骨動脈は同側の星状神経節支配であり，脳底動脈は両側の星状神経節の double innervation である．後大脳動脈は，variation が著明で53例のうち12例が完全に同側の上頸神経節，36例が上頸神経節由来優位を示し，5例は星状神経節優位を示した．また椎骨動脈が同側の上頸神経節支配を示したのが53例のうち7例あつた．以上のことより，Willis 輪及び椎骨動脈は個々の動物によ

り，上頸神経節及び星状神経節によつて variably に支配されていることが分つた．臨床的に用いられる星状神経節摘除は椎骨脳底動脈系の動脈に対しては一部 denervation effect を有するが，内頸動脈系の動脈には decentralization effect を有することになる．

稿を終るに臨み終始適切な御助言と御指導を賜つた半田 肇教授，島本暉朗教授，藤原元始助教授，太田富雄講師，田中千賀子講師に深く感謝致します．また種々の機会に御検討，御討議を頂きました和佐野武雄教授，大串直太先生，南風原英之先生，無量林堯氏に深く感謝致します．

尚，本研究は文部省班研究（UDC 611.81：611-42）の対象になり本論文の要旨は同班研究会合（1967年7月），日本自律神経学会（1967年10月），日本脈管学会（1967年11月）において発表した．